

Ocular toxoplasmosis with positive polymerase chain reaction in peripheral blood – report of two cases, São Paulo State, Brazil

Toxoplasmose ocular com reação em cadeia da polimerase positiva em sangue periférico – relato de dois casos, estado de São Paulo, Brasil

Amanda Pires Barbosa^{1,4,*}, Fábio Batista Frederico^{1,2,4,*}, Mariana Previato^{2,4}, Ana Iara da Costa Ferreira^{2,4}, Plínio Pereira Martins Neto^{1,4}, Cristina da Silva Meira^{3,5}, Fernando Henrique Antunes Murata^{2,4}, Vera Lúcia Pereira-Chioccola^{3,5}, Luiz Carlos de Mattos^{2,4}, Cinara Cássia Brandão de Mattos^{2,4}✉

¹ Retinopathy Outpatient Clinic, Hospital de Base da Fundação Faculdade Regional de Medicina (HB-FUNFARME). São José do Rio Preto, SP, Brazil.

² Laboratory of Immunogenetics – Department of Molecular Biology – School of Medicine of São José do Rio Preto (FAMERP). São José do Rio Preto, SP, Brazil.

³ Laboratory of Molecular Biology, Parasites, and Fungi, Instituto Adolfo Lutz (IAL) São Paulo, SP, Brazil.

⁴ FAMERP Toxoplasma Research Group

⁵ IAL Toxoplasma Research Group

* Contributed equally.

FUNDING: This study was supported by research grants from the São Paulo Research Foundation (FAPESP#2009/09168-6; #2009/17540-2; #2013/10050-5; #2013/15879-8; #2014/09496-1), Brazilian National Council of Scientific and Technological Development (CNPq #473579/2009-0; #303489/2012-0), Brazilian Coordination for Improvement of Higher Education Personnel (CAPES), and by an institutional grant from the School of Medicine of São José do Rio Preto (BAP-FAMERP). The funders had no role in the study design, data collection and analysis, decision to publish, or preparation of the manuscript.

ABSTRACT

Aims: To describe the use of polymerase chain reaction (PCR) in peripheral blood and demonstrate its importance in the clinical follow-up of patients with ocular toxoplasmosis.

Case description: Two immunocompetent patients were clinically diagnosed with acute ocular toxoplasmosis. The routine clinical evaluation consisted of fundus examination using binocular indirect ophthalmoscopy, color fundus photography, fluorescein angiography, and spectral domain optical coherence tomography. The serological diagnosis was made by enzyme-linked immunosorbent assay (ELISA) and confirmed by enzyme-linked fluorescent assay (ELFA). The molecular diagnosis was made by PCR in peripheral blood using the *B1* gene of *Toxoplasma gondii* as marker. The younger patient was male, had previous lesion in the right eye, complained of low visual acuity in the left eye and was under treatment. The older patient was male, had retinal detachment, and presented with sudden loss of acuity in the right eye. The fundus examination revealed chorioretinal scar in the left eye. IgG was reactive, IgM was non-reactive, and PCR was positive in the peripheral blood of both patients. New blood samples were collected for serological and molecular monitoring and PCR remained positive in both cases. Six weeks after treatment with oral sulfadiazine and pyrimethamine, the PCR yielded negative results.

Conclusions: The results show that *T. gondii* antigens may be found in peripheral blood during ocular reactivations and that PCR may be a good tool for the follow-up of patients with ocular toxoplasmosis.

KEY WORDS: *Toxoplasma gondii*; toxoplasmosis, ocular; retinochoroiditis; chorioretinitis; retinography; optical coherence tomography; PCR; polymerase chain reaction

RESUMO

Objetivos: Descrever o uso da reação em cadeia da polimerase (PCR) no sangue periférico e demonstrar sua importância no acompanhamento clínico de pacientes com toxoplasmose ocular.

Descrição dos casos: Dois pacientes imunocompetentes foram clinicamente diagnosticados com toxoplasmose ocular aguda. Rotineiramente, a avaliação clínica foi feita por fundoscopia com o uso de oftalmoscópio binocular indireto, retinografia colorida, angiografia fluorescente e tomografia de coerência óptica espectral. A sorologia foi realizada por ensaio imunoenzimático (ELISA) e confirmada por ensaio imunoenzimático fluorescente ELFA (IgG, IgM). O diagnóstico molecular foi realizado por PCR em sangue periférico usando o gene *B1* de *Toxoplasma gondii* como marcador. O paciente mais jovem era do sexo masculino, apresentava lesão prévia no olho direito, queixa de baixa acuidade visual no olho esquerdo e estava sob tratamento. O paciente mais velho era do sexo masculino, apresentava descolamento de retina e súbita diminuição de visão no olho direito. A fundoscopia revelou cicatriz coriorretiniana no olho esquerdo. Ambos os pacientes tinham IgG reagente, IgM não reagente e PCR positivo em sangue periférico. Novas amostras de sangue foram coletadas para monitoramento sorológico e molecular e a PCR permaneceu positiva em ambos os casos. Seis semanas após o início do tratamento com sulfadiazina e pirimetamina oral, os resultados do PCR tornaram-se negativos.

Conclusões: Os resultados mostram que antígenos de *T. gondii* podem ser encontrados em sangue periférico durante as reativações oculares e que a PCR parece ser uma boa ferramenta para o acompanhamento de pacientes com toxoplasmose ocular.

DESCRIPTORIOS: *Toxoplasma gondii*; toxoplasmose, ocular; retinocoroidite; coriorretinite; retinografia; tomografia de coerência óptica; PCR; reação em cadeia da polimerase

Received: July, 2015

Accepted: December, 2015

✉ Correspondence: Cinara.Brandao@famerp.br



This article is licensed under a Creative Commons Attribution 4.0 International license, which permits unrestricted use, distribution, and reproduction in any medium, provided the original publication is properly cited.
<http://creativecommons.org/licenses/by/4.0/>

Abbreviations: PCR, polymerase chain reaction; CDC, Center for Disease Control; OT, ocular toxoplasmosis; *T. gondii*, *Toxoplasma gondii*; IgG, immunoglobulin G; IgM, immunoglobulin M; ELFA, enzyme-linked fluorescent assay; ELISA, enzyme-linked immunosorbent assay; OCT, optical coherence tomography; DNA: deoxyribonucleic acid; RE, right eye; LE, left eye; TMP/SMX, trimethoprim/sulfamethoxazole; FAMERP, Faculdade de Medicina de São José do Rio Preto; IAL, Instituto Adolfo Lutz.

INTRODUCTION

Infection caused by *Toxoplasma gondii* affects a large proportion of the world's population irrespective of social status. It is responsible for many morbidities both in humans and in animals, which include, among others, ocular toxoplasmosis, cerebral toxoplasmosis, congenital toxoplasmosis, abortion, and stillbirth [1-4]. About 80% of individuals with acquired infection remain asymptomatic, but eye injuries can occur in some cases [5].

Ocular toxoplasmosis (OT) is the most common cause of posterior uveitis worldwide, being more severe in Brazilian patients than in European ones due to the variability of *T. gondii* strains [6-10]. It may affect the fetus, and clinical manifestations may occur during the intrauterine period or after birth, either in childhood or adulthood, with varying degrees of eye involvement [5,9,11-14].

OT is a common disease in the Northwestern Region of São Paulo State, in Brazil. A previous report shows that around 27% of patients treated at an ophthalmology outpatient clinic had clinical evidence of OT [15]. Contact with soil and pets was regarded as an important risk factor for *T. gondii* infection, which also affects about 65% of pregnant women in this region [16-18]. These data are consistent with reports from other Brazilian regions [5,19-21].

Due to significant morbidity associated with OT and the consequent interest in its investigation, new strategies for early laboratory diagnosis and clinical intervention in patients with acute toxoplasmosis have been described [22-29]. Silveira et al. [30] demonstrated the presence of genomic DNA of *T. gondii* by polymerase chain reaction (PCR) in patients with acute OT. Mattos et al. [25] proved the existence of genomic DNA in the peripheral blood of patients with chronic OT in Brazil. Other reports from Colombia [29,31] and Cuba [32] revealed that PCR has contributed to the clarification of the pathophysiology, clinical picture,

monitoring, management, and treatment of OT and of congenital toxoplasmosis.

The objective of this study was to describe the use of PCR in peripheral blood and to demonstrate its importance in the follow-up of two patients with clinical OT. The study was approved by the Research Ethics Committee of the School of Medicine of São José do Rio Preto, Brazil (FAMERP; no. 050/2009 dated March 9, 2009) and both patients and caregivers signed the written informed consent forms after being informed about the nature of the study, including the objectives and laboratory procedures that would be performed.

CASES DESCRIPTION

Two patients were admitted and routinely treated at the Ophthalmology Outpatient Clinic of Fundação Faculdade Regional de Medicina – Hospital de Base, a tertiary teaching hospital in São José do Rio Preto, São Paulo, Brazil. They were clinically diagnosed with toxoplasmic retinochoroiditis.

FIRST CASE

A 16-year-old white male had a complaint of low visual acuity in the left eye (LE) for one week. He was on trimethoprim/sulfamethoxazole (TMP/SMX) prescribed by an ophthalmologist at another outpatient clinic. He had a history of toxoplasmosis in the right eye (RE) five years ago. The corrected visual acuity was 20/20 in the RE and 20/70 in the LE. The ophthalmoscopic examination showed exudative lesions with ill-defined borders in the superior temporal region of the LE and a retinochoroidal scar in the inferior temporal region of the RE. The biomicroscopic examination did not show any changes in the RE, but flare 2+/4+ and cell 1+/4+ were detected in the LE.

Serological analyses were non-reactive for immunoglobulin (Ig) but reactive for IgG. PCR was positive for *T. gondii* in peripheral blood. Treatment with TMP/SMX was maintained for six weeks, in addition to prednisolone acetate 1% ophthalmic drops and 1% cyclopentolate drops for two weeks and 40 mg/day of oral prednisone for 10 days. Recurrence of posterior uveitis and a satellite lesion were observed after seven weeks (**Figure 1**). The patient remained non-reactive for IgM but the PCR in blood was positive. Sulfadiazine, pyrimethamine, folinic acid and prednisolone were then reintroduced for another six weeks. **Figure 2** shows the retinal scars.

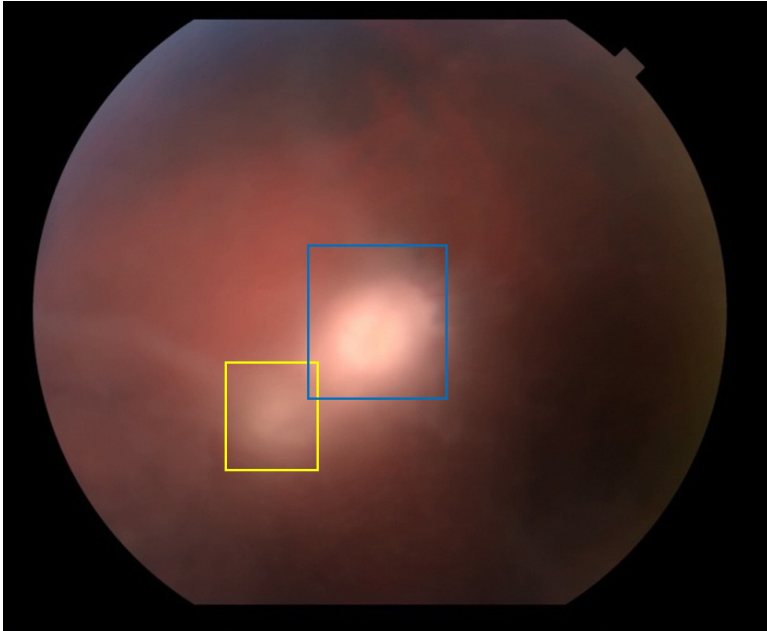


Figure 1. Case 1. Color fundus photography showing temporal region of younger patient's left eye. Posterior uveitis after 7 weeks of first treatment showing active retinochoroiditis. Satellite lesion of toxoplasmic retinochoroiditis (yellow rectangle) and primary retinochoroidal lesion (blue rectangle).

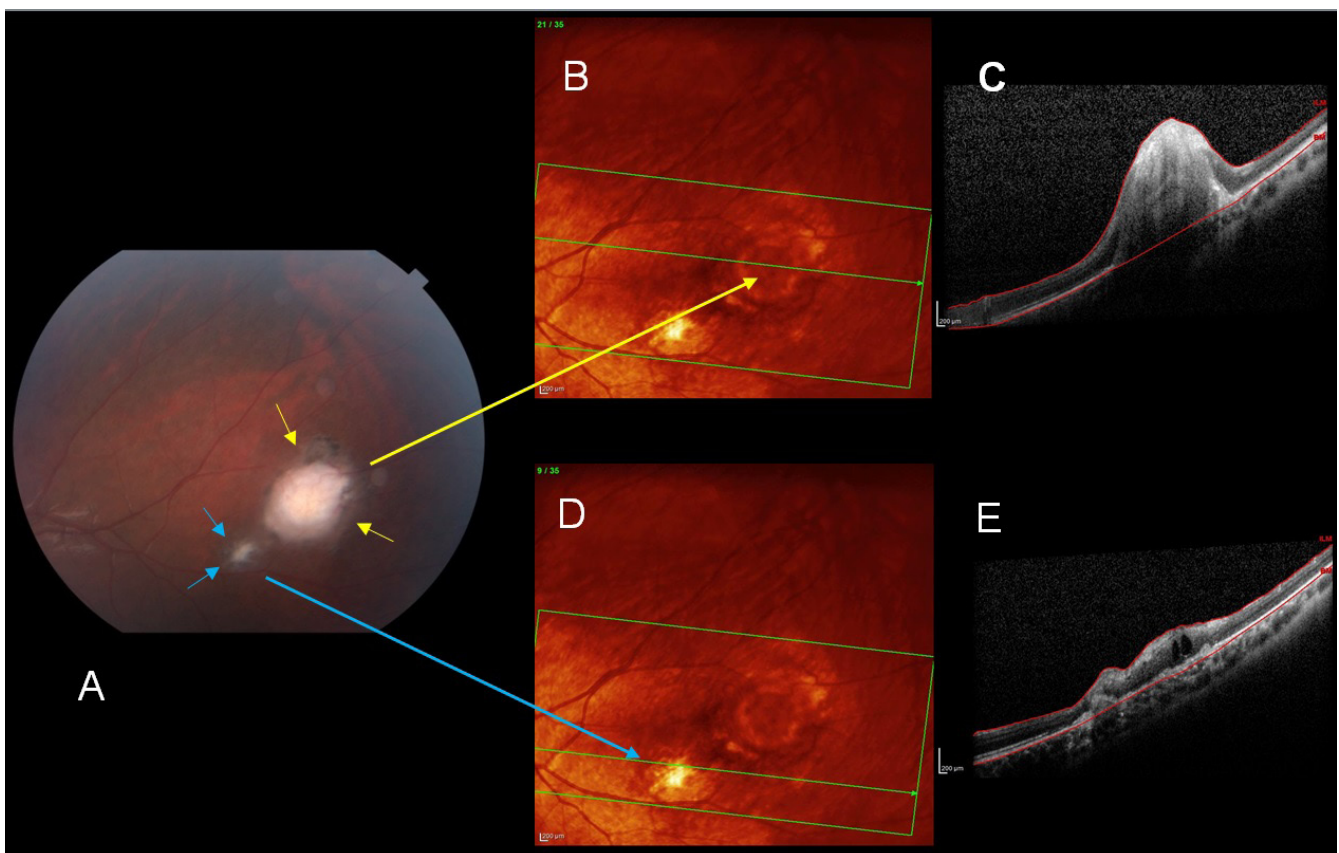


Figure 2. Case 1. Good healing, evidenced in the temporal region of the left eye by the beginning of pigmentation, after 6 weeks of treatment with pyrimethamine and sulfadiazine. **A:** Color fundus photography. Primary toxoplasmic retinochoroidal lesion (yellow arrows) and satellite lesion (blue arrows). Note the improvement of posterior uveitis in relation to Figure 1. **B:** Optical coherence tomography image of temporal region of the left eye at the tip of the yellow arrow, showing primary retinochoroidal lesion. **C:** Profile image of retinal layers where retinal pigment epithelium is observed with process of hypertrophy and disruption of retinal layers. **D:** Optical coherence tomography, same image as in B, showing temporal region of the left eye. Satellite lesion with well-defined borders (blue arrow tips). **E:** Profile image of retinal layers with satellite lesion, showing retinal edema and local healing process. Atrophic and hypertrophic areas of the retinal pigment epithelium and small local edema.

SECOND CASE

A 62-year-old black male had total retinal detachment in the RE and low visual acuity for four months. The ophthalmological evaluation of both eyes by biomicroscopy showed nuclear cataract grade 2; the fundus examination showed proliferative vitreoretinopathy with total retinal detachment in the RE and retinochoroidal scar in the nasal region of the LE (**Figure 3**).

Anti-*T. gondii* IgM was negative and anti-*T. gondii* IgG was positive. PCR was positive for the *B1* gene

of *T. gondii* in peripheral blood. The uncorrected visual acuity was classified as HM (hand motion) in the RE and 20/20 in the LE. The patient was treated with sulfadiazine, pyrimethamine and folinic acid for six weeks.

Ophthalmologic evaluation (Figures 1-3). Funduscopic examination was done by binocular indirect ophthalmoscopy, 20D lens (Binocular Ophthalmoscope ID 10, Topcon Corporation, USA). Ocular toxoplasmosis was diagnosed by visualization of the retina and description of the characteristics, site, and size of exudative lesions or scars [15,25].

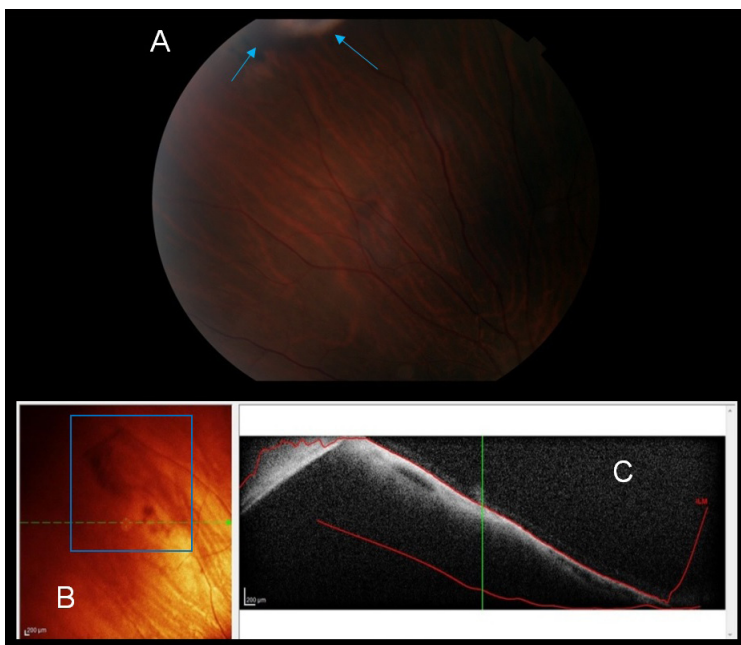


Figure 3. Case 2 (before treatment). **A:** Color fundus photography of upper region of the left eye showing retinochoroidal scar (blue arrows). **B** and **C:** Optical coherence tomography image of the same region of the eye. The blue rectangle shows the toxoplasmic retinochoroidal scar (**B**). Profile of the retina showing disruption of the retinal layers (**C**).

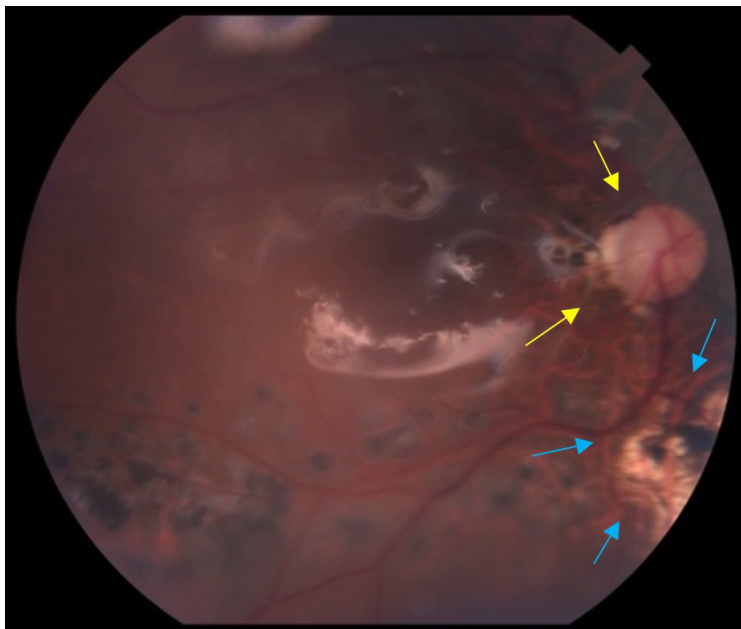


Figure 4. Case 2 (before treatment). Color fundus photography of the right eye. The yellow arrows indicate optic disc pallor while the blue arrows indicate retinochoroidal scar and the presence of silicone oil, documented after vitreoretinal surgery.

An optical coherence tomography (OCT) was performed using an RTVue-100 scanner (Heidelberg Engineering Spectralis OCT, Heidelberg Engineering, CA, USA) with a high axial image resolution and velocity of 26,000 scans per second, in which retinal thickness was measured with the cursor placed according to fixation of the patient or manually in the *fovea centralis*, when the foveal pit was visible. Central macular thickness was also measured.

Radial sections (along horizontal, vertical and cross lines) were obtained from the fundus region, including the toxoplasmic ocular lesion. Whenever possible, three-dimensional OCT of the whole retinochoroiditis lesion was performed. In addition, standardized image acquisition programs such as MM5 (5 × 5 mm² horizontal grid 11 × 11 vertical lines with 668 A-scans each and a 3 × 3 mm² grid of 6 internal vertical and horizontal lines with 400 A-scans each), MM6 (12 radial lines with 1024 A-scans each within 6 mm in diameter), and macula 3D (128 scan lines with 512 A-scans each within 6 × 6 mm²) protocols were used, with all checks with signal strength of at least 40 (range 40.4-79.4) [33].

Serological and molecular monitoring. At admission, new blood samples were collected from both patients for serological and molecular monitoring. PCR remained positive in both cases and the treatment was restarted with oral pyrimethamine and sulfadiazine. Both patients had negative PCR results six weeks after the beginning of treatment.

Serum tests. Blood samples were collected in tubes with and without EDTA in all medical appointments. An investigation of anti-*T. gondii* IgM and IgG antibodies was made in serum samples and DNA was extracted from leukocytes.

Anti-*T. gondii* IgM and IgG antibodies were investigated using the enzyme-linked immunosorbent assay (ELISA) test with ETI-TOXOK-M (IgM) and ETI-TOXOK-G (IgG) commercial kits (DiaSorin, Italy); the results were confirmed by enzyme-linked fluorescence immunoassay (ELFA) VidasToxo IgG and VidasToxo IgM (bioMérieux, France), according to the manufacturer's instructions.

Genomic DNA and PCR. Genomic DNA was extracted from peripheral blood samples collected in 5-mL EDTA tubes, using QIAamp® DNA Blood Mini Kit (Qiagen, Amsterdam, Netherlands). *T. gondii* was identified in blood samples using the B22 and B23 primers, which amplify a 115-base pair (bp) fragment of the repeat region of the *B1* gene, as previously

described [25]. The amplicons were analyzed by electrophoresis in 2% agarose gel, stained with ethidium bromide and visualized under ultraviolet light.

DISCUSSION

Reports on the importance of PCR to demonstrate the specificity and sensitivity necessary for the detection of genetic material of human microorganisms in biological samples have been published elsewhere [22,23,25,26,29,31,32,34,35]. However, this assay is still not requested in the ophthalmologic routine. In this report, we demonstrated that PCR in peripheral blood is useful to detect parasitemia in patients with OT, even after treatment.

Sensitivity and specificity are two important parameters for the evaluation of tools applied in laboratory diagnosis. Our research group obtained 40.8% of sensitivity and 100% of specificity in the detection of *T. gondii* DNA in the peripheral blood of patients with and without OT in a report in which most patients with positive PCR had retinal scars and were positive for anti-*T. gondii* IgG [25].

Although PCR is a good tool for the identification of parasitemia, it does not allow predicting if ocular injuries are caused by reactivation or primary infection by *T. gondii*. However, this report demonstrates that the parasite remains in the circulating blood of patients with chronic OT even when they are treated with antibiotics. These observations are reinforced by additional studies carried out in Brazil and in other South American countries, which have proven the utility of PCR in detecting *T. gondii* DNA in peripheral blood [26,29-32].

Brazilian researchers have recently reported on the treatment options for toxoplasmosis and on new therapeutic targets [36,37]. Nonetheless, there is still no consensus about the best protocol for monitoring clinical cases of toxoplasmosis in humans, especially in countries where there is a great variability of *T. gondii* strains, presence of atypical strains, and severe clinical involvement. TMP/SMX was indicated for treatment of OT, but this drug combination can control parasitemia only for a short period of time [9,38-45].

The cases reported here suggest that conventional PCR targeted at the *B1* gene of *T. gondii* is a good tool for detecting parasitemia and monitoring reactivation of OT even when patients are under antimicrobial treatment.

REFERENCES

- Lopes AP, Dubey JP, Dardé M-L, Cardoso L. Epidemiological review of *Toxoplasma gondii* infection in humans and animals in Portugal. *Parasitology*. 2014;141(13):1699-708. <http://dx.doi.org/10.1017/S0031182014001413>
- Malik A, Rizvi M, Khan F, Khan N, Rabbani T, Khan HM. *Toxoplasma gondii* in women with bad obstetric history and infertility: a five-year study. *Asian Pac J Trop Dis*. 2014;4:S236-9. [http://dx.doi.org/10.1016/S2222-1808\(14\)60446-1](http://dx.doi.org/10.1016/S2222-1808(14)60446-1)
- Nascimento LV, Stollar F, Tavares LB, Cavasini CE, Maia IL, Cordeiro JA, Ferreira MU. Risk factors for toxoplasmic encephalitis in HIV-infected patients: a case-control study in Brazil. *Ann Trop Med Parasitol*. 2001;95(6):587-93. <http://dx.doi.org/10.1080/00034980120073931>
- Silva MMG. Neurologic complications of HIV in the HAART era: where are we? *The Braz J Infect Dis*. 2012;16(4):373-8. <http://dx.doi.org/10.1016/j.bjid.2012.06.021>
- Dubey JP, Lago EG, Gennari SM, Su C, Jones JL. Toxoplasmosis in humans and animals in Brazil: high prevalence, high burden of disease, and epidemiology. *Parasitology*. 2012;139(11):1375-424. <http://dx.doi.org/10.1017/S0031182012000765>
- Khan A, Jordan C, Muccioli C, Vallochi AL, Rizzo LV, Belfort Jr R, Vitor RWA, Silveira C, Sibley LD. Genetic divergence of *Toxoplasma gondii* strains associated with ocular toxoplasmosis, Brazil. *Emerg Infect Dis*. 2006;12(6):942-9. <http://dx.doi.org/10.3201/eid1206.060025>
- Gilbert RE, Freeman K, Lago EG, Bahia-Oliveira LM, Tan HK, Wallon M, Buffolano W, Stanford MR, Petersen E; European Multicentre Study on Congenital Toxoplasmosis (EMSCOT). Ocular sequelae of congenital toxoplasmosis in Brazil compared with Europe. *PLoS Negl Trop Dis*. 2008;2(8):e277. <http://dx.doi.org/10.1371/journal.pntd.0000277>
- Pfaff AWA, De-la-Torre A, Rochet E, Brunet J, Sabou M, Sauer A, Bourcier T, Gomez-Marin JE, Candolfi E. New clinical and experimental insights into Old World and neotropical ocular toxoplasmosis. *Int J Parasitol*. 2014;44(2):99-107. <http://dx.doi.org/10.1016/j.ijpara.2013.09.007>
- Maenz M, Schlüter D, Liesenfeld O, Schares G, Gross U, Pleyer U. Ocular toxoplasmosis past, present and new aspects of an old disease. *Prog Retin Eye Res*. 2014;39:77-106. <http://dx.doi.org/10.1016/j.preteyeres.2013.12.005>
- Jones JL, Parise ME, Fiore AE. Neglected parasitic infections in the United States: toxoplasmosis. *Am J Trop Med Hyg*. 2014;90(5):794-9. <http://dx.doi.org/10.4269/ajtmh.13-0722>
- Boothroyd JC, Grigg ME. Population biology of *Toxoplasma gondii* and its relevance to human infection: do different strains cause different disease? *Curr Opin Microbiol*. 2002;5(4):438-42. [http://dx.doi.org/10.1016/S1369-5274\(02\)00349-1](http://dx.doi.org/10.1016/S1369-5274(02)00349-1)
- Braakenburg AMD, Crespi CM, Holland GN, Wu S, Yu F, Rothova A. Recurrence rates of ocular toxoplasmosis during pregnancy. *Am J Ophthalmol*. 2014;157(4):767-73.e2. <http://dx.doi.org/10.1016/j.ajo.2014.01.004>
- Furtado JMJ, Winthrop KLK, Butler NJ, Smith JR. Ocular toxoplasmosis I: parasitology, epidemiology and public health. *Clin Experiment Ophthalmol*. 2013;41(Febbruary):82-94. <http://dx.doi.org/10.1111/j.1442-9071.2012.02821.x>
- Arantes TE, Silveira C, Holland GN, Muccioli C, Yu F, Jones JL, Goldhardt R, Lewis KG, Belfort Jr R. Ocular Involvement Following Post-natally Acquired *Toxoplasma gondii* Infection in Southern Brazil: A 28-Year Experience. *Am J Ophthalmol*. 2015. <http://dx.doi.org/10.1016/j.ajo.2015.02.015>
- Ferreira AIC, De Mattos CCB, Frederico FB, Meira CS, Almeida GC Jr, Nakashima F, Bernardo CR, Pereira-Chioccola VL, De Mattos LC. Risk factors for ocular toxoplasmosis in Brazil. *Epidemiol Infect*. 2014;142(1):142-8. <http://dx.doi.org/10.1017/S0950268813000526>
- Rodrigues A, Uezato S, Vono M, Pandossio T, Spegiorin LCJF, Oliani AH, Vaz Oliani DCM, Brandão de Mattos CC, de Mattos LC. Non-association between anti-*Toxoplasma gondii* antibodies and ABO blood group system. *J Venom Anim Toxins incl Trop Dis*. 2011;17(2):184-9. <http://dx.doi.org/10.1590/S1678-91992011000200009>
- Gonçalves MAS, Mattos CCB, Spegiorin LCJF, Oliani DCMV, Oliani AH, de Mattos LC. Seropositivity rates for toxoplasmosis, rubella, syphilis, cytomegalovirus, hepatitis and HIV among pregnant women receiving care at a public health service, São Paulo state, Brazil. *Braz J Infect Dis*. 2010;14(6):601-5. [http://dx.doi.org/10.1016/S1413-8670\(10\)70118-5](http://dx.doi.org/10.1016/S1413-8670(10)70118-5)
- Mattos CCB, Cintra JR, Ferreira AIC, Spegiorin LCJF, Galisteu KJ, Machado RLD, de Mattos LC. Lack of association between ABO histo-blood groups, secretor and non-secretor phenotypes, and anti-*Toxoplasma gondii* antibodies among pregnant women from the northwestern region of Sao Paulo State, Brazil. *Arch Med Sci*. 2008;4(3):254-8.
- Mendes NHD, Oliveira CBS, Garcia CA, Holanda CMXC, Andrade-Neto VF. Epidemiological and serological profiles of ocular toxoplasmosis in the municipality of Natal, northeastern Brazil. *Trans R Soc Trop Med Hyg*. 2014;108(10):656-61. <http://dx.doi.org/10.1093/trstmh/tru113>
- Dantas SSBA, Fernandes ARF, Souza Neto OL, Mota RA, Alves CJ, Azevedo SS. Occurrence and risk factors associated with *Toxoplasma gondii* and *Neospora caninum* infections in dogs in the county of Natal, Rio Grande do Norte state, Northeastern Brazil. *Ciência Rural*. 2013;43(11):2042-8. <http://dx.doi.org/10.1590/S0103-84782013001100020>
- Silva LLA, Andrade RRO, Carneiro ACA V, Vitor RRWA. Overlapping *Toxoplasma gondii* Genotypes Circulating in Domestic Animals and Humans in Southeastern Brazil. *PloS One*. 2014;9(2):e90237. <http://dx.doi.org/10.1371/journal.pone.0090237>
- Costa JG, Carneiro AC, Tavares AT, Andrade GM, Vasconcelos-Santos DV, Januário JN, Menezes-Souza D, Fujiwara RT, Vitor RW. Real-time PCR as a prognostic tool for human congenital toxoplasmosis. *J Clin Microbiol*. 2013;51(8):2766-8. <http://dx.doi.org/10.1128/JCM.00982-13>
- Previato M, Frederico FB, Murata FH, Siqueira RC, Barbosa AP, Silveira-Carvalho AP, Meira CS, Pereira-Chioccola VL, Gava R, Martins Neto PP, de Mattos LC, Brandão de Mattos CC. A Brazilian report using serological and molecular diagnosis to monitoring acute ocular toxoplasmosis. *BMC Res Notes*. 2015;8:746. <http://dx.doi.org/10.1186/s13104-015-1650-6>
- Fricke-Hidalgo H, Cimon B, Chemla C, Darde ML, Delhaes L, L'ollivier C, Godineau N, Houze S, Paris L, Quinio D, Robert-Gangneux F, Villard O, Villena I, Candolfi E, Pelloux H. *Toxoplasma* seroconversion with negative or transient immunoglobulin M in pregnant women: myth or reality? A French multicentre retrospective study. *J Clin Microbiol*. 2013;51(7):2103-11. <http://dx.doi.org/10.1128/JCM.00169-13>
- Mattos CCB, Meira CS, Ferreira AIC, Frederico FB, Hiramoto RM, Jr GC, Mattos LC, Pereira-Chioccola VL. Contribution of laboratory methods in diagnosing clinically suspected ocular toxoplasmosis in Brazilian patients. *Diagn Microbiol Infect Dis*. 2011;70(3):362-6. <http://dx.doi.org/10.1016/j.diagmicrobio.2011.02.002>

26. Novais EA, Commodaro AG, Santos F, Muccioli C, Maia A, Nascimento H, Moeller CT, Rizzo LV, Grigg ME, Belfort R Jr. Patients with diffuse uveitis and inactive toxoplasmic retinitis lesions test PCR positive for *Toxoplasma gondii* in their vitreous and blood. *Br J Ophthalmol*. 2014;98(7):937-40. <http://dx.doi.org/10.1136/bjophthalmol-2013-304184>
27. Oréface JL, Costa RA, Scott IU, Calucci D, Oréface F. Spectral optical coherence tomography findings in patients with ocular toxoplasmosis and active satellite lesions (MINAS Report 1). *Acta Ophthalmol*. 2013;91(1):e41-7. <http://dx.doi.org/10.1111/j.1755-3768.2012.02531.x>
28. Villard O, Cimon B, L'Ollivier C, Fricker-Hidalgo H, Godineau N, Houze S, Paris L, Pelloux H, Villena I, Candolfi E. Serological Diagnosis of *Toxoplasma gondii* Infection: Recommendations from the French National Reference Center for Toxoplasmosis. *Diagn Microbiol Infect Dis*. 2015;84(1):22-33. <http://dx.doi.org/10.1016/j.diagmicrobio.2015.09.009>
29. Blanco PJ, Assia YM, Montero YM, Orozco KE. ELFA IgG anti-*Toxoplasma* y PCR anidada para el diagnóstico de toxoplasmosis en mujeres gestantes de Sincelejo, Colombia. *Infectio*. 2011;15(4):253-8. [http://dx.doi.org/10.1016/S0123-9392\(11\)70739-1](http://dx.doi.org/10.1016/S0123-9392(11)70739-1)
30. Silveira C, Vallochi AL, Rodrigues da Silva U, Muccioli C, Holland GN, Nussenblatt RB, Belfort R, Rizzo LV. *Toxoplasma gondii* in the peripheral blood of patients with acute and chronic toxoplasmosis. *Br J Ophthalmol*. 2011;95(3):396-400. <http://dx.doi.org/10.1136/bjo.2008.148205>
31. Gómez-Marín JEJ, de-la-Torre A, Barrios P, Cardona N, Álvarez C, Herrera C. Toxoplasmosis in military personnel involved in jungle operations. *Acta Trop*. 2012;122(1):46-51. <http://dx.doi.org/10.1016/j.actatropica.2011.11.019>
32. Andújar BR, Pe-a MSR, Nodarse JF, Rivero LR, Fernández FAN, Puebla LEJ. Aplicación de herramientas serológicas y moleculares para el diagnóstico de coriorretinitis por *Toxoplasma gondii*. *Rev Cubana Med Trop*. 2013;65(1):13-25.
33. Sull AC, Vuong LN, Price LL, Srinivasan VJ, Gorczynska I, Fujimoto JG, Schuman JS, Duker JS. Comparison of spectral/Fourier domain optical coherence tomography instruments for assessment of normal macular thickness. *Retina*. 2010;30(2):235-45. <http://dx.doi.org/10.1097/IAE.0b013e3181bd2c3b>
34. Belaz S, Gangneux J-P, Dupretz P, Guiguen C, Robert-Gangneux F. A 10-year retrospective comparison of two target sequences, REP-529 and B1, for *Toxoplasma gondii* detection by quantitative PCR. *J Clin Microbiol*. 2015;53(4):JCM.02900-14. <http://dx.doi.org/10.1128/JCM.02900-14>
35. Olariu TR, Remington JS, Montoya JG. Polymerase chain reaction in cerebrospinal fluid for the diagnosis of congenital toxoplasmosis. *Pediatr Infect Dis J*. 2014;33(6):566-70. <http://dx.doi.org/10.1097/INF.0000000000000256>
36. Barbosa MA, Angelin LG, Saikawa GIA, Oliveira CJS, Silva SS, Vendruscolo JW, Marinello PC, Fujita TC, Rocha SPD, Watanabe MAE, Mitsuka-Bregano R, Costa IN. Potenciais alternativas terapêuticas em estudo para a toxoplasmose congênita: uma revisão bibliográfica. *Rev Patol Trop*. 2015;44:1-11. <http://dx.doi.org/10.5216/rpt.v44i1.34798>
37. Mancini DT, Assis LC, Ramalho TC, Cunha EF, Franca TCC. Toxoplasmose: Perspectivas no Estudo de Novos Alvos Terapêuticos. *Rev Virt Quím*. 2012;4(4):434-55.
38. Paquet C, Yudin MH. Toxoplasmosis in pregnancy: prevention, screening, and treatment. *J Obstet Gynaecol Can*. 2013;35(1):78-81. [http://dx.doi.org/10.1016/S1701-2163\(15\)31053-7](http://dx.doi.org/10.1016/S1701-2163(15)31053-7)
39. Nakao M, Yamamoto I, Yamamoto H. Successful treatment of ocular toxoplasmosis that developed four years after kidney transplantation. *Transpl Int*. 2015;28(3):363-5. <http://dx.doi.org/10.1111/tri.12433>
40. Schallhorn JM, Gonzales J. Ocular toxoplasmosis: the treatment dilemma. *J AAPOS*. 2013;17(5):454-5. <http://dx.doi.org/10.1016/j.jaapos.2013.08.001>
41. Kijlstra A, Petersen E. Epidemiology, pathophysiology, and the future of ocular toxoplasmosis. *Ocul Immunol Inflamm*. 2014;22(2):138-47. <http://dx.doi.org/10.3109/09273948.2013.823214>
42. Pleyer U, Alió JL, Barisani-Asenbauer T, Le Hoang P, Rao NA. *Immune Modulation and Anti-Inflammatory Therapy in Ocular Disorders*. Berlin, Heidelberg: Springer Berlin Heidelberg; 2014. <http://dx.doi.org/10.1007/978-3-642-54350-0>
43. Jensen KD, Camejo A, Melo MB, Cordeiro C, Julien L, Grotenbreg GM, Frickel EM, Ploegh HL, Young L, Saeij JP. *Toxoplasma gondii* Superinfection and Virulence during Secondary Infection Correlate with the Exact ROP5/ROP18 Allelic Combination. *mBio*. 2015;6(2):e02280-14. <http://dx.doi.org/10.1128/mBio.02280-14>
44. Avelino MM, Amaral WN, Rodrigues IM, Rassi AR, Gomes MB, Costa TL, Castro AM. Congenital toxoplasmosis and prenatal care state programs. *BMC Infect Dis*. 2014;14(1):33. <http://dx.doi.org/10.1186/1471-2334-14-33>
45. Grigg ME, Dubey JP, Nussenblatt RB. Ocular toxoplasmosis: lessons from Brazil. *Am J Ophthalmol*. 2015;159(6):999-1001. <http://dx.doi.org/10.1016/j.ajo.2015.04.005> 