



Detection of root fractures in glass fiber and metal cast dowel-restored teeth: Accuracy of Computed Tomography vs Digital Radiography

Marlene Tavares de Lima Rezende^a, Francine Kühn Panzarella^b, Marjorie Fonseca da Cunha^b, João Batista Souza^a, José Luiz Cintra Junqueira^b, Cecília Pedroso Turssi^c

ABSTRACT

Objective: Detection of root fractures in dowel-restored teeth is challenging. Even though cone-beam computed tomography (CBCT) has shown higher sensitivity than intraoral radiography, artifacts may be generated in the presence of intraradicular posts. This study assessed the accuracy and reproducibility of CBCT and digital radiography (DR) in detecting root fractures in teeth restored with metal cast dowel and core (MCDC) or glass fiber dowel and resin composite core (GFDRCC). An additional aim was to evaluate the presence of beam hardening artifacts in CBCTs, especially in teeth restored with glass fiber dowel.

Methods: Roots of bovine incisors were endodontically prepared, filled, sealed and randomly divided into two groups to receive MCCDC or GFDRCC (n=15). CBCTs and DRs were obtained prior to and after fracture induction.

Results: CBCT were more accurate than DR in detecting root fractures in dowel-restored teeth. Beam hardening was observed in 100% of CBCT obtained from teeth restored with MCDC and in 93% of those in which GFDRCC had been used. Inter-observer agreement was moderate for both CBCT and DR images.

Conclusion: Regardless of the dowel type, even though beam hardening had been observed in virtually all dowel-restored teeth, CBCT was the most accurate diagnostic tool in detecting root fractures.

Key words: Cone-beam computed tomography; Dental radiography; Tooth root; Dental restoration failure; Validity of tests; Reliability of results.

^a Department of Restorative Dentistry, School of Dentistry, Federal University of Goiás, Goiânia, GO, Brazil

^b Department of Oral Radiology, São Leopoldo Mandic Institute and Dental Research Center, Campinas, SP, Brazil

^c Department of Restorative Dentistry, São Leopoldo Mandic Institute and Dental Research Center, Campinas, SP, Brazil

Detecção de fraturas radiculares em dentes restaurados com pinos de fibra de vidro e núcleo metálico fundido: acurácia da tomografia computadorizada e da radiografia digital

RESUMO

Introdução: A detecção de fraturas radiculares em dentes restaurados com retentores intrarradiculares é desafiadora. Embora a tomografia computadorizada de feixe cônico (TCFC) se mostre com maior sensibilidade que as radiografias intraorais, na presença de pinos intrarradiculares, pode haver artefatos. O objetivo do presente foi avaliar a acurácia e a reprodutibilidade da TCFC e de radiografias digitais (RD) na detecção de fraturas radiculares em dentes restaurados com núcleo metálico fundido (NMF) ou pino de fibra de vidro com núcleo em resina composta (PFVNR). Adicionalmente, foi avaliada a presença de artefatos *beam hardening* nas TCFC, especialmente em dentes restaurados com pinos de fibra de vidro.

Metodologia: Raízes de dentes bovinos foram tratadas endodonticamente, obturadas, seladas e divididas aleatoriamente em dois grupos para receberem NMF ou PFVNR (n=15). TCFCs e RDs foram obtidas antes e após a indução de fratura.

Resultados: A TCFC apresentou maior acurácia que a RD em detectar fraturas radiculares em dentes com retentores. O artefato *beam hardening* foi observado em 100% das TCFCs obtidas em dentes com NMF e em 93% daqueles em que havia PFVNR. A concordância inter-examinador foi moderada para as TCFCs e as RDs.

Conclusão: Independentemente do tipo de retentor, embora o artefato *beam hardening* tenha sido observado virtualmente em todos os dentes com retentores, a TCFC foi a ferramenta com maior acurácia no diagnóstico de fraturas radiculares.

Palavras-chave: Tomografia Computadorizada de Feixe Cônico; Radiografia dental; Raiz dentária; Falha de restauração dentária; Validade dos testes; Reprodutibilidade dos testes.

Correspondence:
Cecília Pedroso Turssi
cecilia.turssi@gmail.com

Received: March 18, 2014
Accepted: October 5, 2016

Conflict of Interests: The authors state that there are no financial and personal conflicts of interest that could have inappropriately influenced their work.

Copyright: © 2016 Rezende et al.; licensee EDIPUCRS.

This work is licensed under a Creative Commons Attribution 4.0 International License.



<http://creativecommons.org/licenses/by/4.0/>

INTRODUCTION

Morphofunctional and esthetic recovery of endodontically treated teeth with extensive loss of crown structure require intraradicular posts to retain the coronal restoration [1]. Despite satisfactory clinical results of the metal cast cores and dowels over the course of years, rigid posts have been related to catastrophic failures [2,3] while glass fiber posts have been described to provide better stress dissipation and less root fractures [4].

The radiological imaging armamentarium to aid in root fracture detection includes intraoral film or digital radiograph and cone beam computed tomography (CBCT) [5]. Although radiographic examinations represent the primary imaging diagnostic method used in patients with suspected root fracture, superimposition of overlying and adjacent structures and beam direction, that is not exactly aligned with, limit the accuracy of intraoral radiographies [5,6]. On the other hand, three dimensional images, as those obtained by CBCT, could allow visualization of the fracture line from different angles and orientations by evaluation of high-resolution cross sections [7,8]. In addition, CBCT images provide high contrast in comparison with those obtained with conventional 2D projections [9].

In fact, previous studies have shown that sensitivity of CBCT in detecting either vertical or horizontal root fracture was significantly higher than that provided by film and digital radiography [5,7,10]. However, the presence of intraradicular posts and luting agents in the field of interest of CBCT, mainly due to the beam-hardening effect, may generate streaking and cupping artifacts [11,12]. As a result, practitioners may face false-negative and false-positive diagnosis of root fractures [13]. While accuracy of CBCT in diagnosing root fractures can be more than 90% in metallic-free restored teeth [14], in metallic post-restored counterparts accuracy have been reported to vary from 38 to 83% [15,16].

Although glass fiber-restored teeth are more likely to suffer amenable and thereby less catastrophic failures, it is demanding that radiological image tools can also provide reliable diagnosis of the presence, if so, of root fractures and of their extent. To the authors' knowledge, to date only one study has examined the accuracy of CBCT in detecting fractures in glass fiber post-restored teeth [17].

If one considers that the beam-hardening effect and consequently streaking artifacts might not only occur in teeth restored with metal cast dowel but also with glass fiber posts, which are also radiodense [18], it can be anticipated that reliability of CBCT in glass fiber restored-teeth may also be compromised by such image artifacts. However, such potential artifacts produced by glass fiber posts in CBCT remain an unexplored issue. There is only a speculation that resin-fiber dowels would possess a uniform energy absorption and, thus, might produce fewer image artifacts [17]. One should, however, bear in mind that in the cited article examiners were not asked to report on image artifacts.

Based on the rationales presented above, this study was devised to compare the accuracy and reproducibility of CBCT and digital radiography (DR) in detecting root fractures in teeth restored with metal custom cast dowel and core or glass fiber post and resin composite core. An additional aim was to evaluate the presence of beam hardening artifacts in CBCTs. The null hypothesis tested was that there would be no difference in the accuracy and reproducibility provided by CBCT and DR in detecting root fractures in teeth restored with metal custom cast dowel and core or glass fiber post and resin composite core.

METHODS

This study was reviewed and approved by the Committee on Animal Research and Ethics, São Leopoldo Mandic School of Dentistry (protocol 2011/0075).

This study was set up as a single factor experiment at two levels arranged in a completely randomized design. The experimental units were 30 endodontically treated roots of bovine incisors, which were randomly divided into two groups ($n = 15$), to receive a metal custom cast dowel and core or a glass fiber dowel and resin composite core. Sensitivity, specificity and accuracy were calculated for each of the diagnostic imaging systems (CBCT and DR). In addition, inter-examiner agreement was determined for both CBCT and DR.

Thirty bovine mandibular incisors were scaled free of remaining soft tissues, polished with pumice slurry and stored in 0.1% thymol solution. Teeth were sectioned 15 mm from apex using a low-speed water-cooled diamond saw (Isomet 1000, Buehler, Lake Bluf., IL, USA). Roots were inspected for cracks under 10x magnification using a stereoscopic microscope.

Root canal treatment followed the chemomechanical preparation using the alternated rotary motions-technique (ARM). After establishment of apical patency, canals were instrumented by the step-back technique up to a #50 K-type endodontic files (Maillefer, Ballaigeus, Switzerland). A 1.0% NaOCl solution (Asfer Ind. Quimica, São Caetano do Sul, SP, Brazil) was used as irrigant. Then, root canals were dried with absorbent paper points (Dentsply, Petropolis, RJ, Brazil), obturated with gutta-percha (Dentsply, Petropolis, RJ, Brazil) and a calcium hydroxide-based sealer (Sealer 26, Dentsply, Petropolis, RJ, Brazil) using the lateral condensation technique. Sealer was manipulated following manufacturer's instructions and filled into the root canal with the aid of digital spacers and a vertical condenser. The excess gutta-percha was removed from the coronal end of the root canal with a warm instrument and the gutta-percha was vertically compacted. All roots were kept at 37°C in 100% relative humidity.

Endodontically treated roots were then randomly allocated into two groups ($n=15$) to be restored with metal cast dowel and core or with a glass fiber dowel and composite core.

For the group that would receive the metal cast dowel and core, root space was prepared using a heated plugger and #1 through #5 Largo drills, leaving 5 mm of gutta-percha to preserve the apical seal. After isolating the root canal with solid Vaseline (Ind. Farm, Rioquímica, São José do Rio Preto, Brazil), a custom dowel and core pattern was fabricated using the self-curing acrylic resin (Duralay, PoliDental, Cotia, SP, Brazil). A groove was made on the lingual surface of the pattern using a spherical diamond bur (no 1016HL, KG Sorensen Ind. Com, Barueri, SP, Brazil). Such a groove was used for positioning the tip of the universal test machine during root fracture induction. Dowel and core patterns were invested and casted in a nickel-chromium-titanium alloy (Fit Cast Titanium, Talladium do Brasil, Curitiba, PR, Brazil).

For the group that would be restored with the tapered-shaped glass fiber dowel (Exacto No. 2, Angelus Ind. Prod. Odontológicos, Londrina, PR, Brazil), root space was prepared using a heated plugger and a spherical diamond bur measuring 1.8 in diameter, leaving 5 mm of gutta-percha to preserve the apical seal. Root canal was first enlarged with a 2.5-mm diameter, spherical diamond bur (3017HL, KG Sorensen Ind. Com, Barueri, SP, Brazil) up to a depth of 6.5 mm from the coronal border of the root. Finally, enlargement was performed with a 2.9-mm diameter, spherical diamond bur (3018, KG Sorensen Ind. Com., Barueri, SP, Brazil) up to a depth of 3.5 mm from the coronal border of the root.

The glass fiber dowels were sectioned using a high speed handpiece so that in the coronal portion 3 mm would be left. Metal dowels and cores and glass fiber dowels were cleaned with 70% alcohol for 30 s, then washed under running water for 1 min and air dried.

Cast metal dowel-and-cores were luted with a zinc phosphate cement (SS White, Rio de Janeiro, RJ, Brazil), which was manipulated according the manufacturer's instructions. This luting agent was then inserted into the root canal using a Lentulo spirals (Dentsply Maillefer, Ballaigues, Switzerland) and applied on dowel-and-core's surface, which was positioned into the root canal. After 5 min of digital pressure, excess was removed.

Glass fiber dowels were treated with a silane agent (3M-ESPE, Saint Paul, MN, USA) for 1 min, after which they were air dried for 5 s. Surrounding dentin and root canal were etched with 37% phosphoric acid (Condac, Detscare Joinville, SC, Brazil) for 15 s. Roots were then rinsed with air/water spray for 15 s and dried with leafs and points of absorbent paper. Next, root canal and surrounding dentin was primed (Scotchbond MP 3M Espe, St. Paul, MN, USA) to receive the adhesive agent (Scotchbond MP 3M Espe, St. Paul, MN, USA), which was light-cured (Ultrablue DMC, DMC, São Carlos, SP, Brazil) for 20 s.

Glass fiber dowels were luted with a resin cement (RelyX ARC, 3M Espe, St. Paul, MN, USA), which was manipulated following the manufacturer's recommendations and inserted into the root canal, as previously described. Cement excess was removed and light-curing was made through the dowel in the apical-occlusal, vestibular, and lingual directions of the root, for 40 s each. Subsequently,

composite cores (Filtek Z250, 3M Espe, St. Paul, MN, USA) were incrementally made with the same dimensions of the metal cast core. A groove was also created to accommodate the tip of the universal testing machine on the lingual surface of the composite core.

Dowel-and-core restored roots were dipped into liquefied wax (Dent Bras, Pirassununga, SP, Brazil) forming a 0.5-mm thick layer and embedded in polyester resin (Polydyne, Hutchinson Brazil, Taboão da Serra, SP, Brazil) to simulate bone support. Solidified wax was removed and the corresponding space was filled with a polyether (Impregum F, 3M Espe, St. Paul, MN, USA) to simulate the periodontal ligament. Each embedded dowel-and-core restored root was designated a specimen.

The radiographic images were obtained using the X-ray machine Astex Odontomax® (Astex, Sao Paulo, SP, Brazil), operated at 70 kVp, 7 mA, with 0.4 s exposure and focus-film distance of 40 cm, using phosphor plates DenOptix QST® (Gendex, Des Plaines, IL, USA). Digital images were acquired with resolution of 8 bits and 300 dpi, and saved as JPEG. Images was evaluated in a LCD flat screen 17" with a resolution of 1280 x 1024 pixels, maximum color quality (12 bit) using a dedicated software (VixWin PRO system, Gendex, Des Plaines, IL, USA).

Tomographic images were acquired using the i-CAT CBCT (120 kVp, 5 mA Imaging Sciences, Hatfield, PA, USA) using the acquisition protocol with FOV of 6 cm and voxel of 0.20 mm (0.4 s of exposure). Images were evaluated using the already mentioned LCD flat screen using a dedicated software (XoranCAT, version 3.1.62; Xoran Technologies, Ann Arbor, MI, EUA). Adjustments were made with the filter "Angio_Sharpen_high 5X5" and with brightness and contrast tools.

Primary reconstruction was performed with maximum resolution and, subsequently, the secondary reconstruction with 1.0-mm slice thickness, thereby obtaining axial, sagittal, coronal, and transversal images of the specimens.

Specimens were mounted on a metallic device positioned in a mechanical testing machine (EMIC DL-2000, São José dos Pinhais, PR, Brazil). The load was applied at a 135o angle to the long axis using a 3-mm-diameter steel sphere. The load application point was the center of the lingual surface. Specimens were tested at a 2.0 mm/min crosshead speed until fracture, which was confirmed by direct visual inspection. If undetected, roots were examined under stereomicroscopy and if even under magnification fracture line remained undetected, root was coated with graphite powder to provide localization of the fracture line.

Following fracture induction, final radiographic and tomography images of specimens were obtained as previously described.

Two blinded, independent and calibrated dental radiologists analyzed the radiographic and CBCT images in order to identify the presence or absence of root fractures in radiographic and tomographic images obtained prior to and after root fractures had been induced. The presence of beam-hardening artifact was recorded for CBCT images.

Inter-observer agreement for both DR and CBCT images was estimated using Kappa statistics. Sensitivity (true positive fraction) and specificity (true negative fraction) were calculated for both DR and CBCT images. Using such values, receiver operating characteristic (ROC) analyses were also performed and the areas under ROC curves were calculated for comparing diagnostic accuracy of both radiological images tested, which was classified as follows: from 0.90 to 1.00 = excellent diagnostic tool; from 0.80 to 0.90 = good diagnostic tool; from 0.70 to 0.80 = fair diagnostic tool; from 0.60 to 0.70 = poor diagnostic tool; and from 0.50 to 0.60 = failed diagnostic tool. Statistical analysis was performed using the statistical software package SPSS 20 (SPSS Inc., Chicago, IL, EUA).

RESULTS

Inter-observer Kappa coefficients were moderate for both DR and CBCT images (0.48 and 0.57, respectively).

For the group restored with metal cast dowel and core, considering examiner #1, sensitivity was higher when CBCT (0.82) rather than DR (0.46) was used (Table 1). For examiner #2, the same result was seen, although there was less discrepancy between the sensitivity values calculated for CBCT and DR (0.36 vs 0.27, respectively). Specificity of CBCT was higher than that observed for DR when one considers examiner #1, while no difference was observed between such radiological images in terms of specificity considering examiner #2 (Table 1). In such metal cast dowel and core restored teeth, ROC curve showed that the diagnostic accuracy of CBCT was higher than that of DR as measured by the areas under the ROC curves which were 0.86 (ex. #1) and 0.68 (ex. #2) for CBCT and 0.64 (ex. #1) and 0.49 (ex. #2) for DR, as depicted in Figure 1. Therefore, accuracy of CBCT to diagnose root fractures in teeth restored with metal cast dowel and core can be good (0.86) or poor (0.68) depending on the examiner.

For the group restored with glass fiber dowel and resin composite core, sensitivity of CBCT to diagnose root fractures was higher than that obtained with DR (0.86 vs 0.71, respectively) when one considers examiner #1 (Table 1). Conversely, for examiner #2, who had no capacity to diagnose root fractures when they were actually present, no difference existed between the sensitivity values provided by DR and CBCT. Considering both examiners, calculated specificity values were close or identical for DR and CBCT (Table 1). ROC curve showed that the diagnostic accuracy

of CBCT (ex. #1: 0.74) to diagnose root fractures in teeth restored with glass fiber dowel and composite core can be higher than that of DR (ex. #1: 0.64). Accuracy of CBCT to diagnose root fractures in teeth restored with glass fiber dowel and composite core can be fair (0.74) but depending on the examiner such diagnostic tool can also be considered a failure (Figure 2).

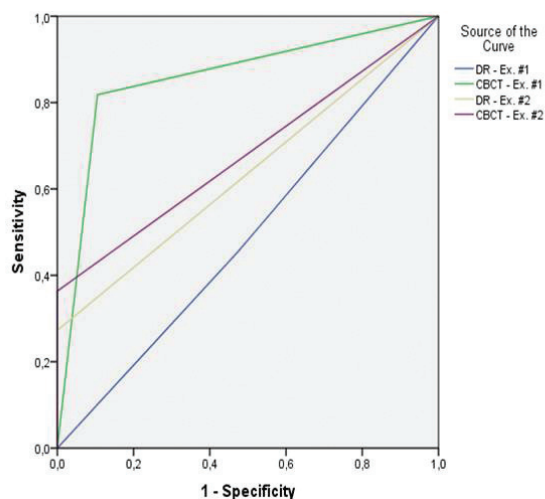


Figure 1. ROC curve of digital radiographic and tomographic images when used to detect root fractures in teeth restored with metal cast dowel and core.

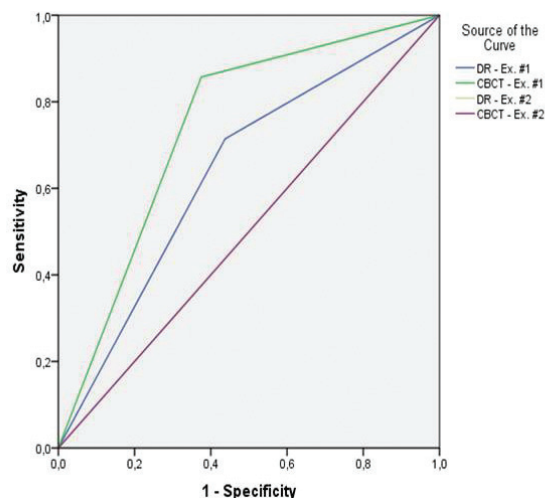


Figure 2. ROC curve of digital radiographic and tomographic images when used to detect root fractures in teeth restored with glass fiber dowel and composite core.

Table 1. Sensitivity and specificity values for DR and CBCT when used to detect root fractures in dowel-restored teeth.

Dowel type	Digital radiography				Cone beam computed tomography			
	Sensitivity		Specificity		Sensitivity		Specificity	
	Ex. #1	Ex. #2	Ex. #1	Ex. #2	Ex. #1	Ex. #2	Ex. #1	Ex. #2
MCDC	0.46	0.27	0.53	1.00	0.82	0.36	0.90	1.00
GFPC	0.71	0.00	0.56	1.00	0.86	0.00	0.63	1.00
Regardless of the dowel type	0.60	0.12	0.54	1.00	0.84	0.16	0.77	1.00

MCDC: metal cast dowel and core; GFPC: glass fiber dowel plus composite core.

Regardless of the dowel type used, sensitivity of DR for examiner #1 was 60.0%, while of CBCT was 84.0% (Table 1). For examiner #2, sensitivity for both radiological imaging was lower (DR: 0.12 and CBCT: 0.16). Specificity values of DR were in the range of 0.54 and 1.00 when considering examiners #1 and #2, respectively (Table 1). For CBCT, specificity was of 0.77 and 1.00 for examiners #1 and #2. Overall, CBCT were more sensitive and specific than DR in detecting fractures in roots restored either with metal cast dowel and core or glass fiber dowel and composite core. ROC curve showed that the diagnostic accuracy of CBCT was higher than that of DR as measured by the areas under the ROC curves which were 0.57 (failure) and 0.81 (good), for DR and CBCT, respectively, as reported by examiner #1. For the other examiner, areas under the ROC curve was in the range of 0.56 for DR and 0.58 for CBCT, both values indicates an inaccurate diagnostic tool.

Beam hardening artifacts were observed in 100% of CBCT obtained from teeth restored with metal cast dowel and core (Figure 3) and in 93% of the CBCT obtained from teeth restored glass fiber dowel (Figure 4).

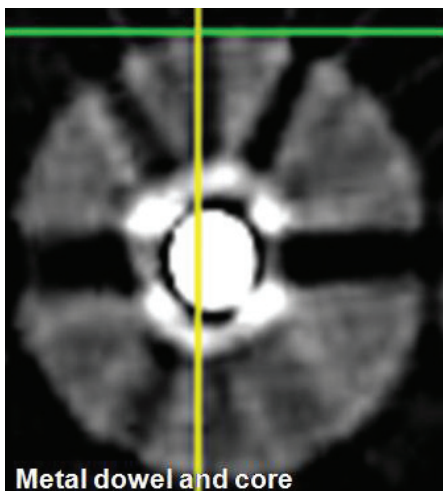


Figure 3. Tomographic images of tooth restored with metal dowel and core showing streaking artifact (arrow).

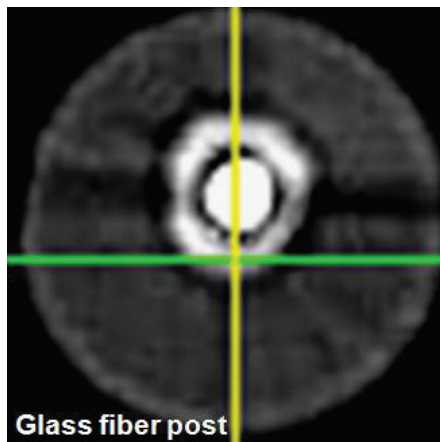


Figure 4. Tomographic images of tooth restored with glass fiber dowel showing streaking artifact (arrow).

DISCUSSION

Accurate diagnosis of root fractures in dowel-restored teeth is crucial for determining an appropriate treatment planning. If in false-negative cases of root fractures patients can present tissue soreness, pocket exudate, swelling, bone loss and abscess formation or even complicate such already existing conditions [19,20], on the other hand, in suspected or false-positive cases unnecessary exploratory surgery and/or extraction may occur [21]. Although recent advances in radiological imaging tools have provided aid in the diagnosis of root fractures especially through CBCT, the reliability of such examination is lower in teeth restored with metallic dowels. Such problem occurs mainly due to the beam-hardening effect and the consequent generation of streaking artifacts, which resemble fracture lines [21].

Although the presence of artifacts has been speculated to be fewer in fiber dowels [17], in this study 93% of glass-fiber restored teeth (93%) showed artifacts in CBCT. This finding may be attributed to the metal elements such as barium that may constitute the glass fibers. Therefore, contrary to a previous theoretical expectation [17] it is unlikely that glass fiber dowels possess uniform energy absorption.

Even in the presence of artifacts, the current study showed that the accuracy of CBCT to diagnose root fractures in teeth restored with glass fiber dowels can be fair and thereby more accurate than DR, which provided poor accuracy (0.64). This may be attributed to the fact that depending on the direction of the central X-ray beam, fractures in roots with no fragment displacement, may not be seen in radiographs [22].

Depending on the examiner, however, both CBCT and DR can be considered inadequate to diagnose root fractures in teeth restored with glass fiber dowels. This finding may be explained by the inconsistency in the inter-examiner agreement, which is in accordance with other studies on the accuracy of CBCT to diagnose root fractures in metal dowel-restored teeth [15,16]. In this study and in various previous investigations, despite the efforts devoted to the calibration process, inter-examiner agreement has been moderate [7,15]. To further minimize inconsistency between examiners, adjustment of brightness and contrast of images were allowed during examinations. It is possible that such adjustments may have somehow contributed to the level of inter-examiner agreement found, since in a previous investigation in which CBCT images were obtained from teeth with metallic dowels, inter-examiner agreement was poorer, within the weak range [16]. In sum, inconsistency among examiners was expected and translates into the reported difficulties in visualizing hypodense lines suggestive of fractures or cracks by professionals [9].

When CBCT was used, teeth restored with glass fiber dowel provided less reliable results in comparison to those restored with metal cast dowel and core. If one considers the percentage of roots in which streaking artifacts were noticed, it would be expected that accuracy would be slightly lower in roots restored with metal cast and dowel core as

artifacts was seen in 100% of their images. Conversely, in roots restored with glass fiber dowels, in which artifacts were observed in 93% of the samples, accuracy was lower. This finding may be explained by the fact that fracture lines was generally narrower and shorter in teeth restored with glass fiber dowels, as noticed at the post-fracture inspection, which in the presence of streaking artifacts would pose additional difficulty in detecting fracture lines, if present. Such narrower and shorter fracture lines may result from the less dentin stress generated by glass fiber dowels [23].

Based on the present findings it can be seen that diagnosis of root fractures in dowel-restored teeth may be even more challenging in the presence of glass fiber dowels. One can argue, however, that less catastrophic failures occur in the presence of glass fiber dowels. Although that is, in fact, an occurrence, it is important that radiological image tools provide reliable diagnosis of the presence, if any, of root fractures and of their extent.

Caution has to be exercised in extrapolating the findings of this laboratory experiment into the clinical setting. Despite the fact that efforts were directed to have a controlled experiment while simultaneously approaching the clinical conditions with the simulation of the periodontal ligament and alveolar bone, it is important to keep in mind that overlying crown and functional occlusal loads were not added to this system. Therefore, although fractures of metal dowel and core had been totally located in the medium and apical third and in glass fiber dowel restored teeth fractures had been located in the coronal third of the roots, fracture propagation may have been unrealistic, since the load was directly applied on the core rather than on a crown over such core.

In addition, clinically, bone and soft tissues may interfere with fracture visualization [24]. Root canal filling materials can also reduce the specificity and/or sensitivity of CBCT by creating hypodense and hyperdense streaking artifacts [7, 13,14,25].

It is worth noting that although radiological images represent an important tool to diagnose root fractures, the analysis of the clinical signs, such as changes in the periodontal ligament space, bone loss, periodontal pocket formation in an isolated site, presence of abscess, tenderness during mastication, loss of intraradicular retainer, and/or prosthesis mobility should be added to the diagnosis of possible root fractures.

CONCLUSION

Regardless of the dowel type, CBCT was a more accurate diagnostic tool in detecting root fractures. Beam hardening artifacts were observed in all CBCT obtained from teeth restored with metal cast dowel core and almost in the totality of CBCT obtained from teeth restored with glass fiber dowel.

REFERENCES

1. Al-Omiri MK, Mahmoud AA, Rayyan MR, Abu-Hammad O. Fracture resistance of teeth restored with post-retained restorations: an overview. *J Endod.* 2010;36:1439-49.

2. Schwartz RS, Robbins JW. Post placement and restoration of endodontically treated teeth: a literature review. *J Endod.* 2004;30:289-301.
3. Soares CJ, Valdivia AD, da Silva GR, Santana FR, Menezes M de S. Longitudinal clinical evaluation of post systems: a literature review. *Braz Dent J.* 2012;23:135-40.
4. Cormier CJ, Burns DR, Moon P. In vitro comparison of the fracture resistance and failure mode of fiber, ceramic, and conventional post systems at various stages of restoration. *J Prosthodont.* 2001;10:26-36.
5. Kambungton J, Janhom A, Prapayasatok S, Pongsiriwet S. Assessment of vertical root fractures using three imaging modalities: cone beam CT, intraoral digital radiography and film. *Dentomaxillofac Radiol.* 2012;41:91-5.
6. da Silveira PF, Vizzotto MB, Liedke GS, da Silveira HL, Montagner F, da Silveira HE. Detection of vertical root fractures by conventional radiographic examination and cone beam computed tomography - an in vitro analysis. *Dent Traumatol.* 2013;29:41-6.
7. Hassan B, Metska ME, Ozok AR, van der Stelt P, Wesselink PR. Detection of vertical root fractures in endodontically treated teeth by a cone beam computed tomography scan. *J Endod.* 2009;35:719-22.
8. Durack C, Patel S. Cone beam computed tomography in endodontics. *Braz Dent J.* 2012;23:179-91.
9. Youssefzadeh S, Gahleitner A, Dorffner R, Bernhart T, Kainberger FM. Dental vertical root fractures: value of CT in detection. *Radiology.* 1999; 210:545-9.
10. Kamburoglu K, Ilker AR, Grondahl G. Effectiveness of limited cone-beam computed tomography in the detection of horizontal root fracture. *Dent Traumatol.* 2009;25:256-61.
11. Mora MA, Mol A, Tyndall DA, Rivera E. In vitro assessment if local tomography for the detection of longitudinal tooth fractures. *Oral Surg Oral Med Oral Pathol Oral Radiol Endod.* 2007;103:825-9.
12. Patel S. New dimensions in endodontic imaging: Part 2. Cone beam computed tomography. *Int Endod J.* 2009;42:463-75.
13. Melo SL, Bortoluzzi EA, Abreu Jr M, Corrêa LR, Corrêa M. Diagnostic ability of a cone-beam computed tomography scan to assess longitudinal root fractures in prosthetically treated teeth. *J Endod.* 2010;36:1879-82.
14. Wang P, Yan XB, Lui DG, Zhang WL, Zhang Y, Ma XC. Detection of dental root fractures by using cone-beam computed tomography. *Dentomaxillofac Radiol.* 2011;40:290-8.
15. Costa FF, Gaia BF, Umetsubo OS, Cavalcanti MG. Detection of horizontal root fracture with small-volume cone-beam computed tomography in the presence and absence of intracanal metallic post. *J Endod.* 2011;37: 1456-9.
16. Costa FF, Gaia BF, Umetsubo OS, Pinheiro LR, Tortamano IP, Cavalcanti MG. Use of large-volume cone-beam computed tomography in identification and localization of horizontal root fracture in the presence and absence of intracanal metallic post. *J Endod.* 2012;38:856-9.
17. R.I. Ferreira, G. Bahrami, F. Isidor, A. Wenzel, F. Haiter-Neto, F.C. Groppo. Detection of vertical root fractures by cone-beam computerized tomography in endodontically treated teeth with fiber-resin and titanium posts: an in vitro study. *Oral Surg Oral Med Oral Pathol Oral Radiol.* 2013;115:49-57.
18. Soares CJ, Mitsui FH, Neto FH, Marchi GM, Martins LR. Radiodensity evaluation of seven root post systems. *Am J Dent.* 2005;18:57-60.
19. Selden HS. Repair of incomplete vertical root fractures in endodontically treated teeth-in vivo trials. *J Endod.* 1996;22:426-9.
20. Fuss Z, Lustig J, Katz A, Tamse A. An evaluation of endodontically treated vertical root fractured teeth: impact of operative procedures. *J Endod.* 2001; 27:46-8.
21. Fayad MI, Ashkenaz PJ, Johnson BR. Different representations of vertical root fractures detected by cone-beam volumetric tomography: a case series report. *J Endod.* 2012;38:1435-42.
22. Rud J, Omnel KA. Root fractures due to the corrosion. *Scand J Dent Res.* 1970;78:397-403.
23. Hayashi M, Sugeta A, Takahashi Y, Imazato S, Ebisu S. Static and fatigue fracture resistances of pulpless teeth restored with post-cores. *Dent Mater.* 2008;24:1178-86.
24. Patcas R, Müller L, Ullrich O, Peltomäki T. Accuracy of cone-beam computed tomography at different resolutions assessed on the bony covering of the mandibular anterior teeth. *Am J Orthod Dentofacial Orthop.* 2012;141:41-50.
25. Hassan B, Metska ME, Ozok AR, van der Stelt P, Wesselink PR. Comparison of five cone beam computed tomography systems for the detection of vertical root fractures. *J Endod.* 2010;36:126-9.

