



Influence of laser biomodulation around multifilamentary sutures

Ingrid Esteves de Villemor Amaral^a, Ana Carolina Ribeiro N. Silva^a, Ryuichi Hoshi^a, Alena Peixoto Medrado^a, Miguel Gustavo Setubal Andrade^a, Sílvia Regina de Almeida Reis^a

^a Bahiana School of Medicine and Public Health

Abstract

Objective: The influence of low level laser (l 670 nm) was evaluated regarding the foreign body reaction and inflammatory response around silk and polyglactin 910 rapid absorbing sutures.

Methods: Forty rats were divided into control and irradiated groups and in four subgroups represented by the type of suture material and by the study period - 7 and 14 days. After transfixation of the suture material, the irradiated group was submitted to laser therapy (GaAlAs, 670 nm, 9 mW). Through tissue sections stained with HE, foreign body reaction and inflammatory cell infiltration were analyzed around the wires.

Results: Around the silk, foreign body reaction and inflammation were reduced in the groups treated with laser in both periods. Compared to polyglactin 910, laser intensified the presence of multinucleated giant cells. The differences in both sutures and in different groups were not statistically significant.

Conclusion: Laser in absorbable sutures increases the foreign body reaction and inflammation in relation to non-absorbable sutures.

Key words: Laser; Silk; Polyglactin 910; Suture; Inflammation

Influência da biomodulação laser em volta de fios de sutura multifilamentares

Resumo

Objetivo: Avaliou-se a influência da fotobiomodulação laser na reação de corpo estranho e resposta inflamatória ao redor de fios de sutura de seda e poliglactina 910 de rápida absorção.

Métodos: Quarenta ratos foram divididos em dois grupos, controle e irradiado, e estes em quatro subgrupos representados pelo tipo de fio – seda e poliglactina 910 de rápida absorção e pelos períodos de estudo – 7 e 14 dias. Após a transfixação do fio de sutura, o grupo irradiado foi submetido à laserterapia (GaAlAs, 670nm, 9mW). Através de seções teciduais analisou-se a reação de corpo estranho e infiltrado inflamatório em volta dos fios.

Resultados: Ao redor do fio de seda houve redução da reação de corpo estranho e da inflamação nos grupos tratados com laser. No décimo quarto dia a redução da inflamação foi estatisticamente significativa ($p=0,008$). Na presença da poliglactina 910 de rápida absorção, o laser estimulou o aumento de macrófagos e de células gigantes multinucleadas e a manutenção de filamentos do fio apesar das diferenças não serem estatisticamente significantes em relação ao grupo controle.

Conclusão: No fio de sutura absorvível o laser intensificou a reação de corpo estranho e a resposta inflamatória em relação aos fios não absorvíveis.

Palavras-chave: Laser; Seda; Poliglactina 910; Sutura; Inflamação

Correspondence:

Silvia Regina de Almeida Reis
srareis@bahiana.edu.br

Received: May 26, 2015

Accepted: December 15, 2015

Conflict of Interests: The authors state that there are no financial and personal conflicts of interest that could have inappropriately influenced their work.

Copyright: © 2015 Amaral et al.; licensee EDIPUCRS.

Except where otherwise noted, content of this journal is licensed under a Creative Commons Attribution 4.0 International license.



<http://creativecommons.org/licenses/by/4.0/>

Introduction

Still to these days, sutures continue to be the most common method of joining tissue borders when lesioned by trauma or in surgical wounds [1]. Due to the search for an ideal suture material, a great variety of absorbable and non-absorbable materials, derived from animals to synthetic polymers have been commercialized [2]. The reaction of the tissue to any suture results from the lesion induced by the needle insertion and the physical and chemical nature of the material [3].

Silk is a surgical, multifilament suture, non-absorbable, sterile, of animal origin, produced by silkworms [4,5]. It is known for its high tensile resistance and great extensibility [6]. It is composed by two proteins, sericin and fibroin. The fibroin is an insoluble protein present in the center of the silk filament, and it is surrounded by sericin, a soluble protein, considered to be a natural gum and an allergenic principle in people who are sensitive to silk. The fibroin and sericin can be dissociated by boiling, allowing the preparation of a material with few antigenic effects [7,8]. On the other hand, the polyglactin 910 of rapid absorption is an absorbable, synthetic and twisted suture material, composed by a copolymer made of glycolid and lactic acid, coated by polyglactin 370 and calcium stearate and submitted to ionizing radiation [5]. Its tensile strength is lost between 10 to 14 days, with a complete absorption in 42 days [9].

Despite all advances in the properties of these multifilament suture, studies have demonstrated the potential of both materials to cause an inflammatory response around tissues, always associated to the presence of histiocytes and giant multinucleated cells [3,4,10].

Laser biomodulation has been a non medicinal therapeutic resource progressively used in oral tissues submitted to surgeries, aiming at optimizing the post-trauma inflammatory response. However, the effect of such radiation therapy associated to the reaction of a foreign body is still scarce, especially around suture. Therefore, it becomes relevant to evaluate the influence of the low level laser (l 670nm) in the inflammatory response around multifilament silk and rapid absorption polyglactin 910 suture in days 7 and 14 after its insertion in the subcutaneous tissues of rats.

Methods

All the manipulation procedures in animals were performed according to the laws and guidelines of the Ethics Committee in the Use of Animals of the Bahiana School of Medicine and Public Health, and approved by the document No. 007/2008.

The sample consisted of 40 rats, males and females, clinically healthy, weighting on average 200 and 250 grams and with approximately 90 days old, having been bred and maintained in individual cages, with free access to water and a balanced feed.

Under anesthetics with xylazine chloridate (0,5mL) (Sedazine[®], Fort Dodge Animal Health – Iowa, USA) and

ketamine chloridate (2,5ml) (Vetaset[®], Fort Dodge Animal Health – Iowa, USA) diluted in 1 mL saline solution, the transfixation of the silk suture was performed (Shalon suturas[®]) with a diameter of 4-0, manufactured by Shalon LTDA, and rapid absorption polyglactin 910 (vicryl rapid[®]), of 4-0 diameter, manufactured by Ethicon division (Ethicon, Someville, NJ) of Johnson&Johnson (São Paulo, Brazil), in the head to tail direction on the back of each rat [11]. For each animal, only one type of suture material was used.

After the suture procedure, the 40 animals were divided in two groups, control and irradiated, each with twenty animals each, and these were then divided into four subgroups of five animals, represented by the tipe of suture – silk and rapid absorption polyglactin 910, as well as by the period of death – 7 and 14 days.

The suture was cut very close to the orifice made by the needle, implanted at 1,0 cm, and the skin was delicately massaged, leaving the material totally inserted in the tissue, with no contact with the outside [3].

In group 1, the animals were submitted to surgical intervention and the laser treatment was realized with the equipment turned off.

In group 2, treated with laser, the beam was positioned at a distance of 1,0 cm from the interface of the suture and the skin, in four equally distant points, with incidence only on the tissue. The time used for each point was 31 seconds for 1 J/cm². The application sessions were performed in alternative days and had the total duration of 372 and 620 seconds for 12 e 20 J/cm², respectively.

The animals were treated with the GaAIAs semiconductor diode laser, previously calibrated, of continuous emission (wave length of 670nm, with outward power of 9mw, power density of 0,031 W/cm (Dentoflex – São Paulo, Brasil) VR-KC – 610 (Dentoflex – São Paulo, Brazil). In order to determine the time of the cutaneous applications, the size of the spot was measured using a specimeter with scale from 0,1 to 10 mm² and the value of 27,28 mm² was obtained. The quantity of energy density and capacity of the outwards device were determined using the Tunér and Hode equation [12].

During the whole experiment, the animals were kept in a ventilated, warm and clean environment, away from noise stimulation to avoid stress. The sutures were inspected daily aiming at registering any tecidual alteration.

In the respective periods of 7 and 14 days, the animals were put to death through anesthetic deepening. After confirming death, fragments of tissue containing the suture were dried and fixed in formalin at 10%. The fixed material was submitted to routine histological procedure. Sections of 5 mm width were stained in hematoxilín-eosin.

For the analysis of histological cuts, a Motic B5 Professional Series microscope was used. A semi-quantitative study in the cuts stained by hematoxilín-eosin was performed, evaluating the reaction of a foreign body and the inflammatory infiltrate. Criteria according to Kosan et al. [13] were used.

Fisher Exact Test was used to determine the differences between the groups studied. Associations with $p \leq 0,05$ were considered statistically significant.

Results

During the post-surgical period, the animals remained healthy, with normal healing at the place of needle transfixation, with no clinical evidences of infection.

The histological cuts analyzed were relative to the 7th and 14th day after insertion of each type of suture in the subcutaneous tissue at the back of the rats. In the sections stained with hematoxylin-eosin, an area related to the suture material was observed in the hypodermis, which served as the objective of this study.

7 days

Silk

Analysis under light microscopy on the control group sutured with the silk multifilament showed the presence of a foreign body reaction in all studied animals, around the preserved filaments, varying from mild histiocytes infiltrate (20%) to a greater presence of multinucleated giant cells in 80% of the animals. In relation to the low level laser treated group, an absence of foreign body was observed in 40% of the animals, as well as less accentuated levels of multinucleated giant cells surrounding the silk filaments,

in relation to the control group. These differences were not statistically significant (Table 1).

In relation to the inflammatory infiltrate in the group submitted to laser biomodulation, in all animals the presence of a mild mononuclear inflammatory infiltrate was observed around the material and less accentuated levels of inflammatory response in relation to the control group. The differences were not statistically significant (Table 2).

Rapid Absorption Polyglactin 910

Laser and control groups sutures with rapid absorption polyglactin 910 evidenced the presence of foreign body reaction in all studied animals with no statistical differences (Table 1). In this type of suture the laser biomodulation intensified the foreign body reaction with a greater presence of multinucleated giant cells and macrophages, some of them surrounding the fragments (Figure 2).

It was observed that the suture filaments were more preserved in relation to the control group. In most animals the material was already in dissolution phase. In 80% of the control animals, a lower presence of filaments and foreign body reaction around the biomaterial was observed (Table 1, Figure 1).

As to the inflammation, mononuclear infiltrate from moderate to severe were observed in both groups, with no statistical differences (Table 2).

Table 1. Percentual distribution of the foreign body reaction in the control group and in the group treated with laser around silk and rapid absorption polyglactin suture in the periods of 7 and 14 days.

Period of study	Groups	Foreign body reaction				p ⁽¹⁾	Groups	Foreign body reaction			
		Silk			p ⁽¹⁾			Polyglactin 910			p ⁽¹⁾
		Absent %	Level 1 %	Level 2 %				Absent %	Level 1 %	Level 2 %	
7 days	Control ^a	0	20	80	0,286	Control ^e	0	80	20	0,206	
	Laser ^b	40	40	20		Laser ^f	0	20	80		
14 days	Control ^{c*}	0	60	40	0,079	Control ^{g*}	100	0	0	0	
	Laser ^d	80	20	0		Laser ^h	100	0	0		

(1) Exact Fisher Test, $p \leq 0,05$.

*(cg): statistically significant among the silk and polyglactin 910 control groups in 14 days ($p=0,008$).

Table 2. Percentual distribution of the inflammatory infiltrate in the control group and in the group treated with laser around silk and rapid absorption polyglactin suture in the periods of 7 and 14 days.

Study Period	Groups	Inflammatory infiltrate			p ⁽¹⁾	Groups	Inflammatory infiltrate		
		Silk		p ⁽¹⁾			Polyglactin 910		p ⁽¹⁾
		Level 1 %	Level 2 %				Level 1 %	Level 2 %	
7 days	Control ^a	80	20	1,0	Control ^e	40	60	1,0	
	Laser ^b	100	0		Laser ^f	60	40		
14 days	Control ^{c*}	0	100	0,008†	Control ^{g*}	100	0	0	
	Laser ^d	100	0		Laser ^h	100	0		

(1) Fisher Exact Test, $p \leq 0,05$.

*(cg): statistically significant among silk and vicryl control groups in 14 days ($p=0,008$).

†(cd): statistically significant among the control and laser groups in 14 days ($p=0,008$).

14 days

Silk

All the animals of the control group presented foreign body reaction around the suture in different levels. In the group submitted to laser biomodulation this type of response was only observed in 20% of the animals, however the differences were not statistically significant (Figure 3). In this period, when the control groups of both material were confronted, the differences were significant ($p=0,008$) (Table 1).

In relation to the presence of inflammation, it was observed that, in the control group, there were more accentuated levels of mononuclear cells in 100% of the animals, whereas in the group submitted to laser biomodulation, the degree of

inflammatory response was mild in all animals, despite the differences were not statistically significant. In this same study period, the control groups of both suture material showed statistical significance in relation to the inflammatory response ($p=0,008$) (Table 2).

Rapid absorption Polyglactin 910

Absence of filaments was verified in both study groups in all analyzed animals, as well as the dissolution of biomaterial in some animals (Figure 4). At this point the surrounding connective tissue showed absence of foreign body reaction in both groups (Table 1) and a mild presence of lymphocytes and fibroblasts, besides collagen fibers better organized in the laser group (Table 2, Figure 4).

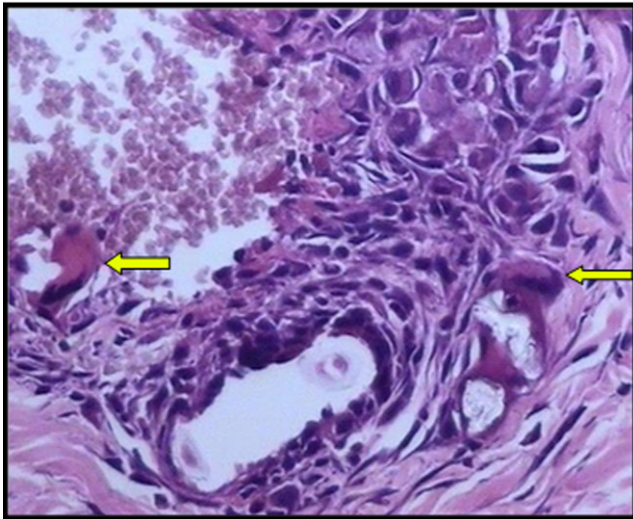


Figure 1. Control group, rapid absorption polyglactin 910, subgroup 7 days. Presence of multinucleated giant cells surrounding fragments of material filaments (*). Observe the little integrity of the remaining filaments (arrows). HE 200X.

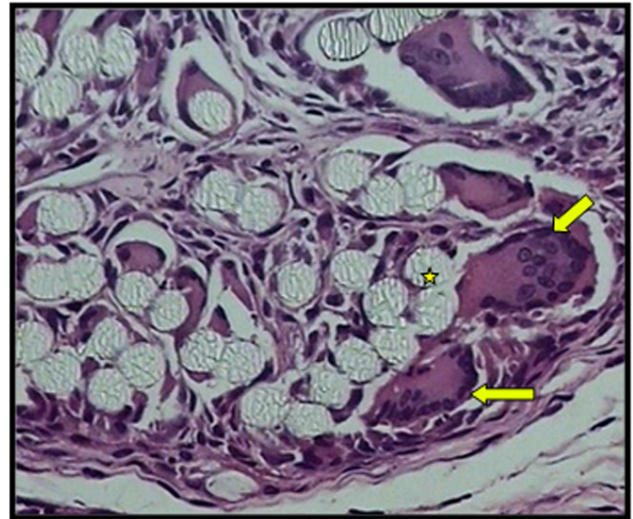

Figure 2. Laser group, rapid absorption polyglactin 910, subgroup 7 days. Presence of multinucleated giant cells (arrows) and integrity of filaments (*). HE 200X.

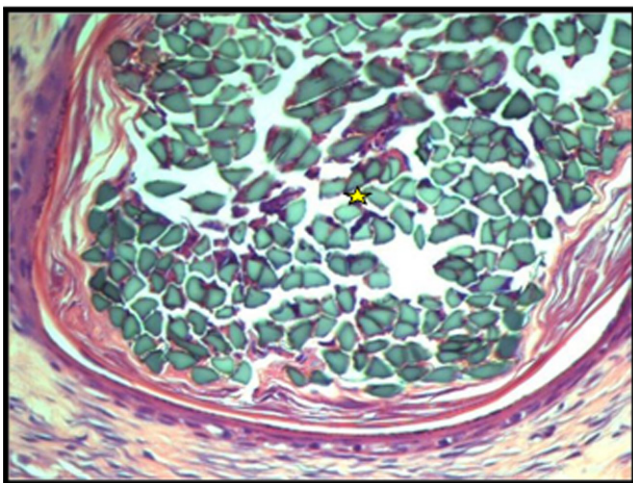


Figure 3. Laser group, silk, subgroup 14 days. Presence of collagen surrounding the suture and absence of inflammation between the filaments.(*). HE 200X

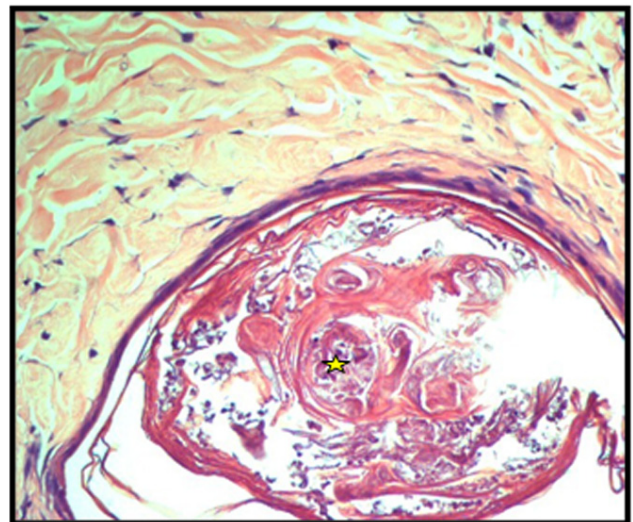


Figure 4. Laser group, rapid absorption polyglactin 910, subgroup 14 days. Presence of dissolved biomaterial (*). HE 100X.

Discussion

The objective of this work was to evaluate how does the subcutaneous tissue of rats behave in relation to the multifilament suture silk and rapid absorption polyglactin 910 suture, associated to GaAIA's laser biomodulation. The developed methodology sought to eliminate the interference of trauma due to incision and divulsion. That way, using only the needle orifice, the material was inserted in the rat hypodermis. This model of suture transfixation was also employed by Silva et al. [14], Andrade et al. [3], Biondo-Simões et al. [11]. In order to study the inflammatory and foreign body response around these two different multifilament materials, periods of 7 and 14 days were used.

Despite multifilamentary silk has been widely used in sutures of oral cavities, it is known that this material causes an inflammatory response in the tissues, generally associated to foreign body reaction [4,10]. These findings corroborate with our study, where there presence of multinucleated giant cells were found in all studied animals in both periods of 7 and 14 days. Martínez-lage et al. [10] verified a late foreign body reaction to the suture silk material in myelomeningocele repair, whereas Calkins et al. [15] showed the formation of abscess using the same material in inguinal hernia.

Adding light laser therapy to the suture surrounding the silk material, a reduction in foreign body reaction was observed, especially on the 14th day, when 80% of the irradiated animals did not show this type of response. The multifilamentary suture allow for capillary penetration in bacteria and fluids in its interstices, besides favouring an inflammatory response [15]. Arcuri et al. [5] report that the material of multifilamentary sutures accumulate more biofilm in comparison to monofilamentary, whereas Banche et al. [16] show that the silk suture has a low capacity of bacterial adherence. The material inserted at the back of animals, in our study, were free from infection.

Uff et al. [17] demonstrated *in vitro* that soluble products of the silk suture have the potential to activate macrophages, whose cytokine, the TNF- α , promotes cellular activation and evidences the inflammatory potential of the material. This cytokine performs a relevant role in the formation of epitheloid cells derived from the macrophages, that merge, also under the action of TNF- α , in order to form the multinucleated giant cells. The macrophage also participates in the absorption of polyglactin 910 suture. A study of an experimental model similar to ours, using the rapid absorption polyglactin 910 suture showed macrophages and multinucleated giant cells surrounding filaments [3]. These results are similar to those found in the control group of the present experiment. On the addition of phototherapy, a greater foreign body reaction was observed in the absorbable material, with the presence of filaments still preserved on the 7th day. Such increase in the foreign body reaction was also documented by Silva et al. [14], using the laser 1670 nm and fluency of 4 J/cm², with a similar irradiation to that used in our study. Rocha et al. [18] observed an increase in

the granulomatous response around glass slides on the back of mice submitted to laser biomodulation (1820-904nm).

In the period of 14 days in both irradiated and control groups, all the filaments of rapid absorption polyglactin 910 were already very dissolved, verifying only the presence of mud and a mild inflammatory infiltrate. The findings of the control group corroborated with the work of Aderriotis e Sándor [2] (1999).

Conclusions

Low level laser therapy, in the parameters used herein, associated to multifilamentary non-absorbable suture silk suture induced lower levels of inflammatory and foreign body reaction responses. In the absorbable multifilamentary rapid absorption polyglactin 910 suture, the laser λ 670 nm biomodulation induced a more exacerbated foreign body reaction, with preservation of the filament at the 7th day of study. It is understood that this phototherapy interfered in the activation of macrophages and in the liberation of material degradation products. Based on these results, it is suggested that the low level laser can be used in silk sutured surgical wounds and its indication in wounds sutured with rapid absorption polyglactin 910 material should be used with caution.

References

1. Zimmer CA, Thacker JG, Powell DM, Bellian KT, Becker D G, Rodeheaver G T, et al. Influence of knot configuration and tying technique on the mechanical performance of sutures. *J Emerg Med* 1991;9: 107-13.
2. Aderriotis D, Sándor GKB. Outcomes of irradiated polyglactin 910 vicryl rapide fast-absorbing suture in oral and scalp wounds. *J Can Dent Assoc* 1999;65:345-47.
3. Andrade MGS, Weissman R, Reis SRA. Tissue reaction and surface morphology of absorbable sutures after *in vivo* exposure. *J Mater Sci: Mater Med* 2006;17:949-61.
4. Shalon fios cirurgicos LTDA. Seda. [acesso em 01 de abril de 2010]. Disponível em: www.shalonsuturas.com.br/Bulas%20Shalon/SEDAS.pdf.
5. Arcuri C, Cecchetti F, Dri M, Muzzi F, Bartuli FN. suture in oral surgery. A comparative study. *Minerva Stomatol* 2006;55:17-31.
6. Hakimi O, Gheysens T, Vollrath F, Grahn M F, Knight DP, Vadgama P. Modulation of cell growth on exposure to silkworm and spider silk fibers. *J Biomed Mater Res A* 2010;92(4):1366-72.
7. Kurosaki S, Otsuka H, Kunitomo M, Koyama M, Pawankar R, Matumoto K. Fibroin allergy: IgE mediated hypersensitivity to silk suture materials. *J Nippon Med Sch* 1999;66(1):41-4.
8. Sofia S, McCarthy MB, Gronowicz G, Kaplan D L. Functionalized silk-based biomaterials for bone formation. *J Biomed Mater Res* 2001;54(1): 139-48.
9. Leroux N, Bujold E. Impact of chromic catgut versus polyglactin 910 versus fast-absorbing polyglactin 910 sutures for perineal repair: a randomized, controlled trial. *American Journal of Obstetrics and gynecology* 2006;194(6):1585-90.
10. Martínez-Lage JF, Níguez BF, Almagro MJ, Rodríguez MC, Pérez-Espejo MA. Foreign body reactions causing spinal cord tethering: a case-based update. *Childs Nerv Syst* 2010;26:601-6.
11. Biondo-Simões MLP, Sech M, Adur RC, Marques LO, Corbellini M, Canalli LS, et al. A comparative study of performance of catgut and polyglactone 25 sutures in rat abdominal walls, contaminated or not. *Acta Cirúrgica Brasileira*. São Paulo. 1997;12(3):163-8.
12. Túner RJ, Hode L. Low Level Laser Therapy. Clinical Practice and Scientific Background. Prima Books: Suécia, 1999.
13. Kosan M, Gonulalan U, Ozturk B, Kulakoglu S, Erguder I, Akdemir O, et al. Tissue reaction of suture materials (polyglactina 910, chromed catgut and polydioxanone) on rat bladder wall and their hole in bladder stone formation. *Urol Res*. 2008;36:43-9.



14. Silva ACRN. Influência da biomodulação laser (670nm) na interface de fios de sutura poliglactina 910 de rápida absorção. [Tese de mestrado]. Salvador (BA): Faculdade de Odontologia – Escola Bahiana de Medicina e Saúde Pública, 2009.
15. Calkins MC, Peter SDS, Balcom A, Murphy PJ. Late abscess formation following indirect hernia repair utilizing silk suture. *Pediatr Surg Int* 2007;23:349-52.
16. Banche G, Roana J, Mandras N, Amasio M, Gallesio C, Allizond V, et al. Microbial adherence on various intraoral suture materials in patients undergoing dental surgery. *J Oral Maxillofac Surg* 2007;65:1503-07.
17. Uff CR, Scott AD, Pockley AG, Phillips R K S. Influence of soluble suture factors on *in vitro* macrophage function. *Biomaterials* 1995;16(5): 355-60.
18. Rocha LLV, Pinto MVM, Maria J, Vieira AJD, Martins PR, Costa KFFV et al. Efeito da laserterapia sobre modelo experimental de inflamação granulomatosa. *Fisiot Bras*, 2007,8(5):335-41.

