



Preclinical evaluation of a xenogenic hydroxyapatite/collagen-based bone substitute material

Rafael Cotias Bittencourt^a, Igor Iuço Castro-Silva^a, Anderson de Oliveira Paulo^b, Débora dos Santos Tavares^c, José Mauro Granjeiro^d

Abstract

Objective: The aim of this study was to evaluate the physical, chemical and biological properties of a bovine xenograft for bone repair.

Methods: Physicochemical analysis was performed using X-ray diffraction, Fourier transform infrared spectroscopy and scanning electron microscopy. *In vitro* biocompatibility was evaluated through cytotoxicity and cell adhesion assays using a fibroblast cell line culture and murine pre-osteoblasts, respectively. Furthermore, an *in vivo* assay using a subcutaneous grafting on a rat model (5 and 10 weeks, synthetic hydroxyapatite as a control material) and yet a long term experiment in critical-size calvarial defects (6 and 9 months, blood clot and autogenous bone as negative and positive controls, respectively).

Results: The test material presented a three-dimensional architecture consisting of dense granules and micropores (various sizes), composed of crystalline hydroxyapatite/collagen fibers. The xenograft was cytocompatible and after 7 days pre-osteoblast spreading on material granules was observed. Histopathological analysis of the implanted material into rat subcutaneous showed the intact xenograft after 10 weeks surrounded by loose connective tissue with a mild inflammatory infiltrate and giant multinuclear cells around the particles (5 and 10 weeks) similar to the synthetic hydroxyapatite. Concerning the critical-size calvarial defects it was observed 1.7 times more new bone formation in the xenograft than the blood clot group ($P < 0.001$), a similar result was verified on autograft. There was no significant variation in the volume density of the xenograft ($37.9\% \pm 4.3$).

Conclusion: It was concluded that the xenogenic material is biomimetic, biocompatible, osteoconductive and non-resorbable, therefore being a promising material for bone repair.

Keywords: Bioprosthesis; materials testing; bone regeneration; apatite; collagen

^a Programa de Pós-Graduação em Odontologia, UFF – Universidade Federal Fluminense, Niterói, RJ, Brazil

^b Curso de Especialização em Endodontia, FACIT – Faculdade de Ciências do Tocantins, Araguaína, TO, Brazil

^c Faculdade de Odontologia, UFS – Universidade Federal de Sergipe, Lagarto, SE, Brazil

^d Diretoria de Metrologia Aplicada às Ciências da Vida, INMETRO – Instituto Nacional de Metrologia, Qualidade e Tecnologia, Duque de Caxias, RJ, Brazil

Avaliação pré-clínica de um material substituto ósseo xenógeno a base de hidroxiapatita/colágeno

Resumo

Objetivo: O objetivo deste estudo foi avaliar as propriedades físicas, químicas e biológicas de um xenoinxerto bovino para o reparo ósseo.

Métodos: Análise físico-química foi conduzida usando difração de raios X, espectroscopia no infravermelho por transformada de Fourier e microscopia eletrônica de varredura. Biocompatibilidade *in vitro* foi avaliada através de ensaios de citotoxicidade e adesão celular usando culturas de linhagem celular de fibroblastos e pré-osteoblastos murinos, respectivamente. Além disso, por ensaio *in vivo* usando enxertia subcutânea no modelo rato (5 e 10 semanas, hidroxiapatita sintética como material controle) e ainda um experimento a longo prazo em defeitos de tamanho crítico em calvária (6 e 9 meses, coágulo sanguíneo e osso autógeno como controles negativo e positivo, respectivamente).

Resultados: O material teste apresentou uma arquitetura tridimensional consistindo de grânulos densos e microporos (várias dimensões), composto de hidroxiapatita cristalina/fibras colágenas. O xenoinxerto foi citocompatível e após 7 dias foi observado espreado de pré-osteoblastos sobre grânulos do material. Análise histopatológica do material implantado no subcutâneo de ratos mostrou o xenoinxerto intato após 10 semanas circundado por tecido conjuntivo frouxo com suave infiltrado inflamatório e células gigantes multinucleadas ao redor de partículas (5 e 10 semanas) similar à hidroxiapatita sintética. Considerando os defeitos de tamanho crítico em calvária foi observada 1,7 vezes mais formação de novo osso no xenoinxerto do que no grupo controle ($P < 0,001$), um resultado similar verificado no autoenxerto. Não houve variação significativa na densidade de volume do xenoinxerto ($37,9\% \pm 4,3$).

Conclusão: Pode-se concluir que o material xenógeno é biomimético, biocompatível, osseocondutor e não-reabsorvível, portanto sendo um material promissor para o reparo ósseo.

Palavras-chave: Bioprótese; teste de materiais; regeneração óssea; apatita; colágeno

Correspondence:
Igor Iuço Castro-Silva
igoriuco@gmail.com

Received: October 30, 2012
Accepted: November 11, 2013

Conflict of Interests: The authors state that there are no financial and personal conflicts of interest that could have inappropriately influenced their work.

Copyright: © 2014 Bittencourt et al.; licensee EDIPUCRS.

This work is licensed under a Creative Commons Attribution-NonCommercial 3.0 Unported (CC BY-NC 3.0).

ISSN: 1980-6523

Introduction

Due to the increasing life expectancy of the world population during the last decades, traumatic, degenerative and chronic diseases of the musculoskeletal system have become a major health, social and economical problem [1]. Extensive bone defects have limited repair potential and, therefore, biomaterials have been studied in order to assist the repair of bone defects which do not regenerate spontaneously. These materials should be biocompatible and also be able to contribute to the reestablishment of the injured tissue function [2-3].

Bone substitute implantable devices may exhibit osteoconductive activity toward the bone growth, functioning as a framework and enabling angiogenesis and bone deposition [2-4]. Nevertheless, they have rarely been described with osteoinductive property (ability to induce undifferentiated cells towards the formation of mineralized bone matrix at non-hard tissue sites) [4], showing an osteogenic potential only when used as carriers of mesenchymal stem cells, pre-osteoblasts or osteoblasts in cell-based therapies [5]. When considering the origin of a bone substitute materials, they can be classified as autografts (donor and receptor being the same individual), allograft (donor and receptor are of the same specie), xenografts (donor and receptor are of different species) or alloplastic grafts (synthesized in laboratories, do not requiring a donor site) [1-3].

Several studies show the superiority of autogenous grafts on inducing of bone repair. However, this type of graft has limitations, such as greater morbidity for the patient due to a second surgical site, its limited availability and higher cost [6]. Allografts, xenografts and alloplastic grafts supply these limitations, presenting biocompatibility, osteoconduction, sometimes promoting osteoinduction, even not presenting any osteogenic property [1,2,7]. Of special interest, xenografts and alloplastic grafts eliminate the need for a human bone bank, a great advantage over the allografts [1].

Xenografts usually have bovine origin [1] and are constituted by hydroxyapatite similarly to the human bone $[\text{Ca}_{10}(\text{PO}_4)_6(\text{OH})_2]$. This type of graft can be deproteinized and/or demineralized, different physicochemical conditions which selectively modulate the tissue response of the host organism [8]. The collagen composition is useful for its intrinsic characteristic of agglutination that assist in the structuring of the composite, having influence on the morphology and size of hydroxyapatite crystals [9,10] and at the same time contributing in the process of osteoblast adhesion onto the biomaterial surface [9]. A scaffold that mimics an inorganic and organic matrix has a relevant role in the bone repair process, presenting a surface that allows cell adhesion and also a three-dimensional structure that allows a network connection between the pores and bone cell ingrowth [11]. A real perspective on bone loss therapies rely on the tissue bioengineering area, associating these natural grafts to osteogenic cells or inductive proteins, which

could still improve the bone repair when using xenografts [1-3,6,12]. Biocompatibility, osteoconduction and low rate resorption in a short time after surgery are favorable properties of xenografts [2,3,9], but long-term studies must be carried out to understand the pattern of biodegradation of xenografts and its influence in bone gain.

In this study, a Brazilian bovine xenograft was evaluated concerning its physicochemical properties, as well as its *in vitro* and *in vivo* compatibility on a short- and long-term experiment, aiming to assess its applicability as a bone graft.

Methods

Physicochemical characterization

A bovine xenogenic material Extra Graft XG13[®] (Silvestre Labs, Rio de Janeiro, RJ, Brazil) was analyzed, containing 75% hydroxyapatite and 25% type I collagen (informed by the manufacturer).

Regarding the physicochemical evaluation of the product, it was first conducted the X-ray diffraction (XRD) to assess the existence of different crystallographic phases in the material, using a high resolution diffractometer HZG4 (Zeiss, Jena, Thuringia, Germany) with CuK α radiation ($\Theta=1,5418\text{\AA}$) and angular scanning of 10-100 $^\circ$ with step 0.05/s. The ionic functional groups such as OH⁻¹, (SO)₄⁻³, CO₃⁻² and H₂O molecules were identified by Fourier transform infrared spectroscopy (FTIR) with Paragon-1000 spectofotometer (Perkin-Elmer, Norwalk, CT, United States). The morphology and topography of calcium phosphate particles were investigated by scanning electron microscopy (SEM) by a JSM 5800LV microscope (Jeol, Tokyo, Japan).

In vitro biological characterization

The cytotoxicity of the material was determined using a protocol described on ISO 10993-5, and three samples of three independent lots (n=9) were prepared according to ISO 10993-12. Mice Balb/3T3 fibroblasts (American Type Culture Collection, Manassas, VA, United States) were cultured in 25 cm² plastic containers with Dubelcco's modified Eagle's medium (DMEM) supplemented with 1.2 g/L NaHCO₃, 0.025 g/L ampicillin, 0.1 g/L streptomycin and 10% fetal bovine serum (FBS) and incubated to 37 $^\circ\text{C}$ in wet atmosphere, with 95% air and 5% CO₂. The ratio used in the extract fabrication was 0.1 g material/1.0 mL DMEM. Dilutions were made from the pure extract (100%) in DMEM to final concentrations of 10%, 1% and 0.1%. The control groups consist of titanium powder grade II + DMEM (negative control) and phenol 0.2% + DMEM (positive control) (Fig. 1A). After 48 hours incubation in 96-well microplate (density of 1.0 x 10⁴ cells/well), semi-confluent cell cultures were treated with different dilutions of the extract for additional 24 hours, including the controls in triplicates. Then, cell monolayers were washed 2 times with saline solution, trypsinized and stored in 4% formaldehyde and counted in a Neubauer chamber. The results were expressed as percentage of the number of viable

cells; the cells cultivated without any material (DMEM + 10% FBS) were considered 100%. The cell counting of the other groups and dilutions were calculated in relation to their respective control group. The mean and standard deviation were subjected to statistical analysis of variance (ANOVA) considering significant differences if $P < 0.05$.

Osteoprogenitor cells from Balb/c mice (FOST) [13], at the density of 5.0×10^4 cells/well, were seeded on 6 disks (8 mm in diameter x 3 mm in height) of the test material and cultured in DMEM containing antibiotics (100 U/mL penicillin and 100 µg/mL streptomycin) and supplemented with 10% FBS for 24 hours (Fig. 1B). Cell culture was maintained at 37°C in a wet atmosphere with 5% CO₂. After 7 days the samples were processed for SEM, being fixed in Karnovsky's solution (3% glutaraldehyde, 1% paraformaldehyde and 0.07 M sodium cacodylate buffer, pH 7.2), dehydrated in ethanol and critical point, metalized in gold and evaluated on a JSM 5800LV microscope (Jeol, Tokyo, Japan).

In vivo biological characterization

All surgical procedures followed the national standardizations of good scientific conduct of Brazilian College of Animal Experimentation (COBEA). This study was approved by the Ethics Committee in Animal Research at the Fluminense Federal University under the protocol numbers CEPA-UFF #04/07 and #51/08.

Biocompatibility and osteoinductive potential of the xenograft was evaluated into rat subcutaneous, using a total of 10 *Rattus norvegicus albinus* (Wistar, 300 g, 2 months, both sexes) and synthetic hydroxyapatite was used as a control. Each animal, under systemic anesthesia with hydrochloride ketamine (60 mg/kg, Francotar, Virbac do Brasil Ltda, Sao Paulo, SP, Brazil) and hydrochloride xylazine (12 mg/kg, Rompum, Bayer S.A., Sao Paulo, SP, Brazil), had on its dorsal medial region the creation of four subcutaneous pockets for implantation of the test material and control, in duplicate (Fig. 1C). During the full experimental period all animals were kept under proper hygiene and care conditions into individual cages at room temperature $21 \pm 3^\circ\text{C}$, noise-free environment and daily cycles of illumination light/dark (12 h each), with food and water ad libitum. Medication to control postoperative pain (2 mg/kg, Meloxicam, Eurofarma, Rio de Janeiro, RJ, Brazil) was given subcutaneously afterwards the surgery and at the following day. Euthanasia by anesthetic overdose was performed at 5 and 10 weeks after implantation and excisional necropsies of skin were fixed with 4% buffered formalin for 48 hours. Tissue samples were dehydrated in ethanol, clarified in xylol, impregnated and included in paraffin. Five-micrometer-thick sections were stained by hematoxylin-eosin for descriptive analysis of healing response, including presence/absence of inflammatory infiltrate, presence/absence of necrosis foci, vascularization, new connective tissue formation, presence of ectopic bone-like tissue and stability of the graft material.

Long-term experimentation was performed using critical-size bone defects (CSD) (3). Animals (n=30, 5 for

each group) were put under systemic anesthesia using the same protocol previously described. The skull was incised for a full-thickness flap and surgical creation of a 8-mm diameter defect on Wistar rats' calvaria with trephine bur (Sistema de Implante Nacional – SIN, Sao Paulo, SP, Brazil), using abundant local cooling with 0.9% physiological saline. The osteomized fragment was removed thoroughly and the defect was fulfilled with one of three experimental groups: blood clot (negative control), autogenous particulate bone from skull (positive control) or xenograft (Fig. 1D-F). Afterwards, the flap was sutured with 5.0 nylon thread (Ethicon®, Johnson & Johnson, Sao Paulo, SP, Brazil), and the animals had the same postoperative care and anti-inflammatory medication described previously. Euthanasia by anesthetic overdose occurred at 6 and 9 months after surgery and the skull samples were fixed with 4% buffered formalin for 48 hours. The excision necropsies of skulls were decalcified in fast bone demineralization solution (Allkimia, Campinas, SP, Brazil) for 48 hours, washed for 1 hour, dehydrated in ethanol, clarified in xylol, impregnated and included in paraffin. Five-micrometer-thick sections were stained by hematoxylin-eosin and examined by an experienced pathologist. A descriptive analysis was performed by comparing the biological response intra and inter-groups, based on the type and intensity of inflammatory alterations and repair processes (fibrosis, new blood vessels and osteogenesis). Photomicrographs were obtained with digital camera Cybershot DSC-W300 (Sony, Manaus, AM, Brazil) connected to a light microscope FWL-1000 (Feldman Wild Leitz, Manaus, AM, Brazil). Digital images of non-superimposed contiguous fields (6-8 *per* slide, $\times 170$ magnification) covered the extension of the rat calvarial CSD and allowed their analysis using Image Pro-Plus 6.0 (Media Cybernetics, San Diego, CA, United States), calibrated in micrometers/pixel and with a 100 points grade. The determination of the number of points upon connective tissue, blood tissue, new bone tissue, old bone tissue and graft biomaterial allowed calculation of volume density of each parameter (3). Two independent and calibrated researchers evaluated the images (maximum media variation lower than 0.01%, paired *t* test (InStat 3.01; Graphpad Software Inc., San Diego, CA, United States). Mean volume density and standard deviation data were subjected to ANOVA and Tukey's test, considering significant differences if $P < 0.05$. For non-normal distributions, it was applied Kruskal-Wallis test as non-parametric analysis.

Results

Physicochemical characterization

XRD confirmed the presence of crystalline peaks corresponding to hydroxyapatite. FTIR showed specific bands that correspond to the collagen and the calcium phosphate/hydroxyapatite. SEM showed the ultrastructure of the xenograft, consisting of dense granules (100-500 µm) made up of crystalline apatite associated to collagen. Material showed micropores and irregular surfaces with

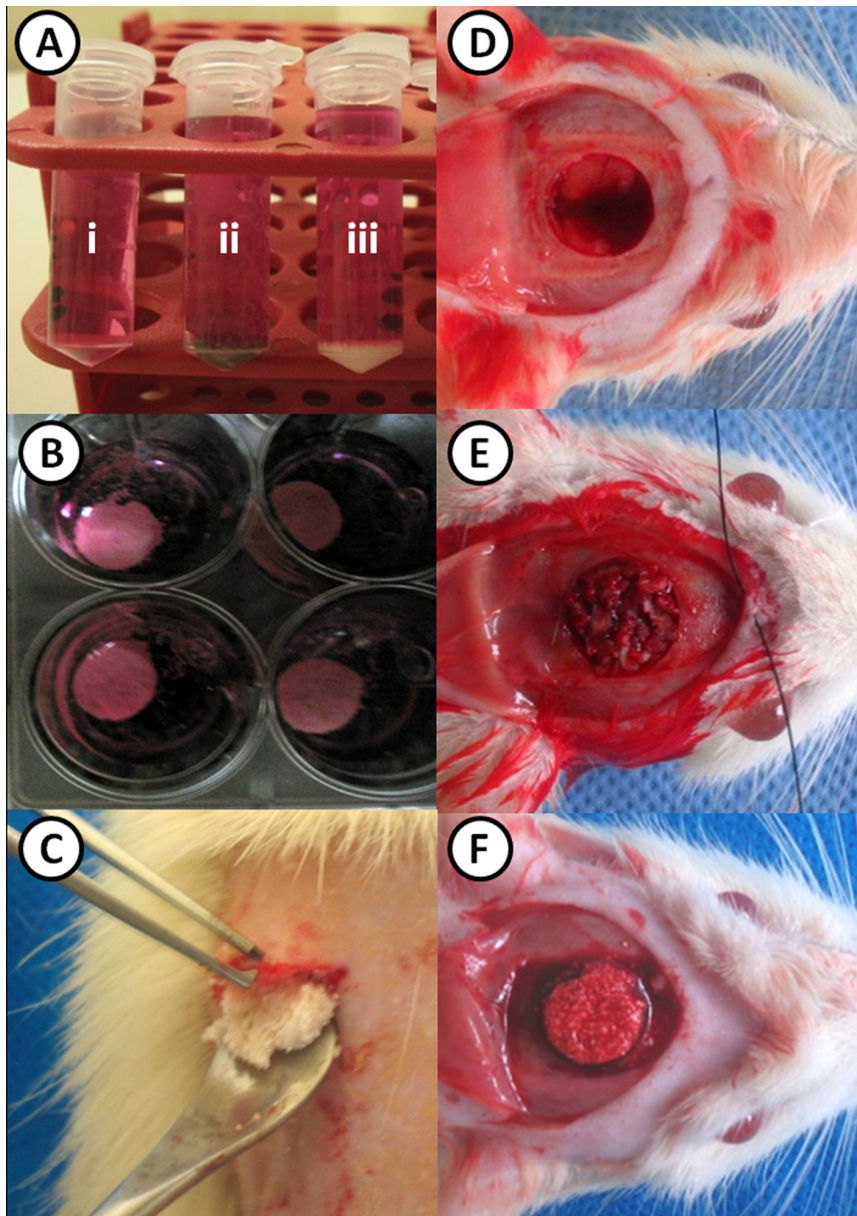


Fig. 1. Biological tests for xenograft. **A:** Preparation of extracts for cytotoxicity assay (i: phenol, ii: titanium and iii: xenograft). **B:** Xenograft disks after cell seeding for adhesion test. **C:** Subcutaneous implantation of xenograft. **D-F:** CSD treated with blood clot (**D**), autogenous bone (**E**) or xenograft (**F**).

multiple hydroxyapatite microparticles presenting less than 5 μm in diameter (Fig. 2).

In vitro biological characterization

Cell viability analysis of the different extract dilutions made from the xenograft samples demonstrated that the material is non-toxic, similar to the negative control (titanium) and significantly different from positive control for toxicity (0.2% phenol). SEM and light microscopy analysis showed adherence and spreading of pre-osteoblasts (FOST) onto the surface of the xenogenic granules and collagen fibers, after 7 days in cell culture (Fig. 3).

In vivo biological characterization

After observing the rat subcutaneous tissue, it was verified no sign of necrosis foci and the xenograft induced the formation of a granulation tissue of a mild to moderate intensity at 5 weeks after surgery. Promptly, one of the five rats in this group suggested the presence of osteoid tissue among xenograft granules. After 10 weeks, xenograft remained intact, surrounded by loose connective tissue with mild inflammatory infiltrate and foreign body-type giant multinucleated cells around the particles. Similar biological behaviors were observed with ectopic grafting of synthetic hydroxyapatite during the experimental period (Fig. 4).

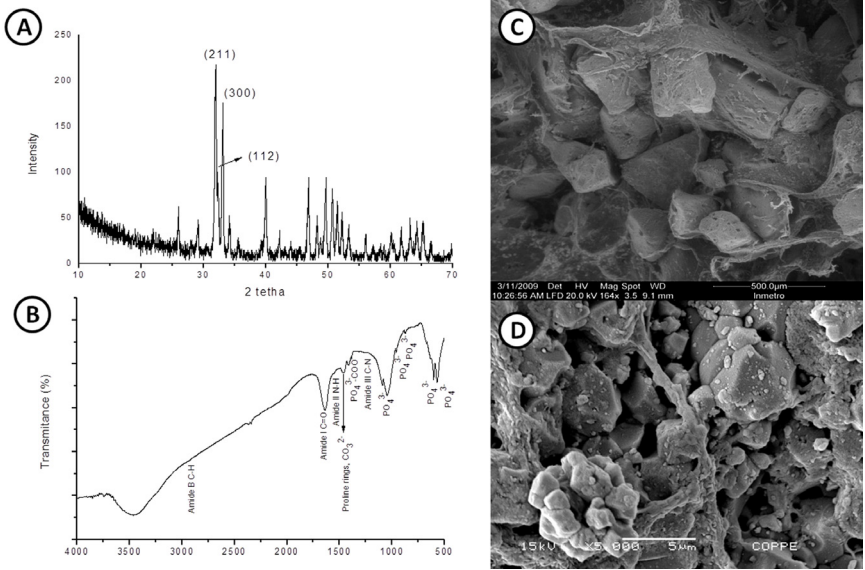


Fig. 2. XRD analysis (A), FTIR analysis (B) and SEM analysis of xenograft (C: granules morphology and D: surface topography).

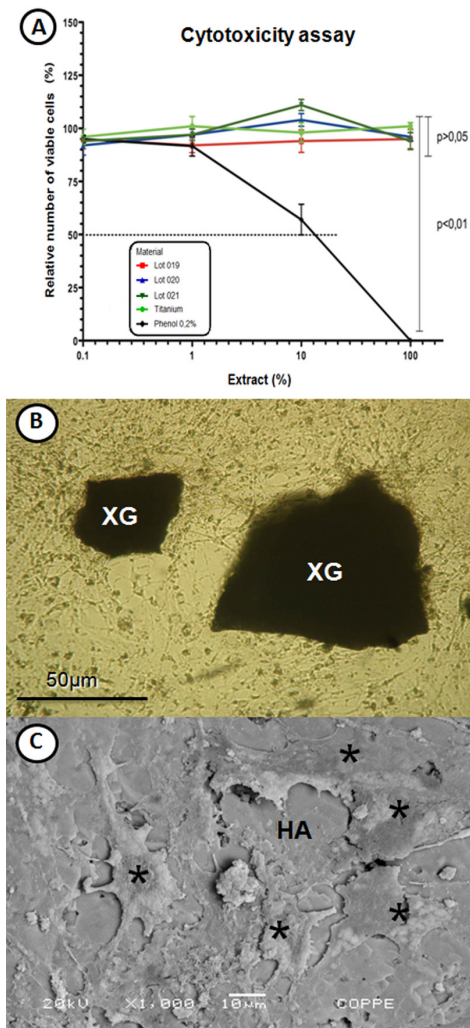


Fig. 3. *In vitro* studies. Cytotoxicity assay, showing viability of mice fibroblasts to the material tested after 24 hours (A). Adhesion test after 7 days, with released particles of xenograft/XG and attachment/spreading of FOST cells onto hydroxyapatite/HA surface in light microscopy (B) and electron microscopy (C).

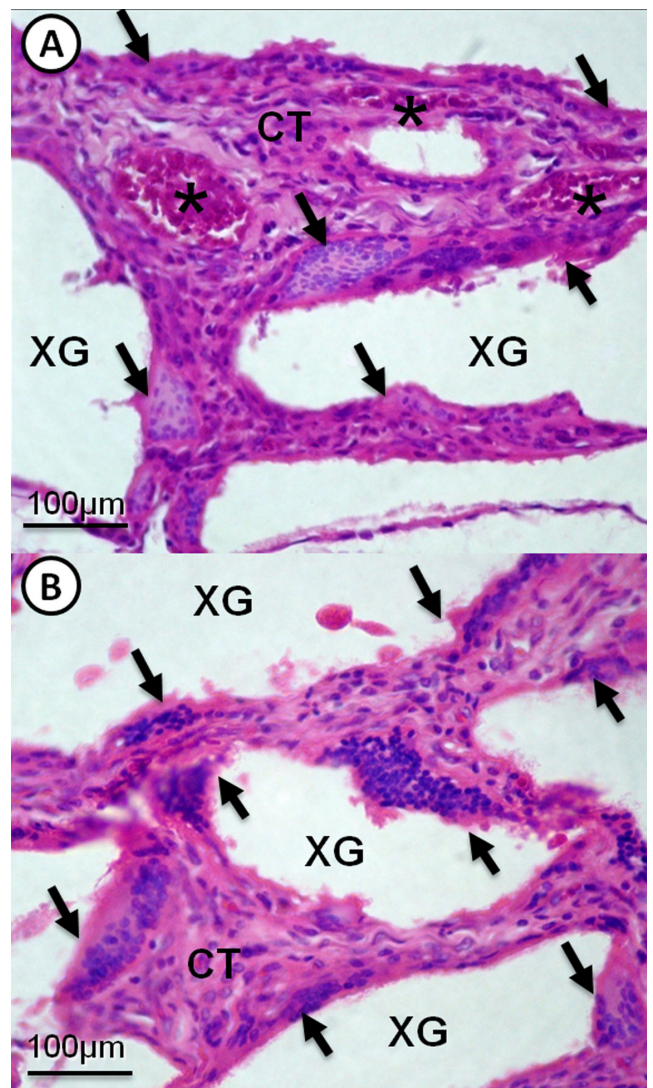


Fig. 4. Rat subcutaneous implantation of xenograft at 5 weeks (A) and 10 weeks (B). XG: xenograft, CT: connective tissue, asterisks: blood vessels and black arrows: foreign body-giant cells.

Histopathological analysis of CSD demonstrated similar biological response between xenograft and autogenous bone groups. After 6 months, in xenograft group there was newly formed bone very close to the biomaterial granules. At 9 months, it was observed 1.7 times more new bone formation in the xenograft than blood clot group ($P<0.001$), which was similar to the result of the autograft group. There was no significant variation in volume density of xenograft group ($37.9\% \pm 4.3$) during the experimental time (Table 1). Xenogenic hydroxyapatite/collagen particles were still present into CSD in large quantities which confirms their characteristic of high crystallinity and non-resorbable, permeated by small spaces of loose connective tissue and some blood vessels. These samples presented greater

stability with respect to the maintenance of its framework, having fewer structures that are beyond the interest of this work and other structures have been called as bleeding, muscle tissue, fat and skin. The presence of bone islets in the middle of CSD surrounded by connective tissue was visible along all experiment in blood clot group (negative control). However, there was no total closure of the defect with new bone tissue, confirming this model as a CSD that does not regenerate during lifetime of the animal. At 9 months, the autogenous bone induced the major closure of CSD with new bone tissue attesting the veracity of this group as a positive control. The presence of blood vessels was also well evidenced in the autograft group (Fig. 5).

Table 1. Mean percentage (standard deviation) of the bone volume density, fibrous connective tissue and residual biomaterial at 6 and 9 months after implantation in CSD (ANOVA and Tukey's test if $P<0.05$).

Analyzed structure (%)	Experimental groups and periods (months)					
	Blood clot		Autogenous bone		Xenograft	
	6	9	6	9	6	9
Bone	9.79±2.13*,†	14.98±4.70*,†	17.99±2.96*	23.67±7.27*	21.43±4.05†	26.03±3.15†
Fibrous tissue	30.23±5.57	27.77±6.30	21.27±5.25	18.86±5.42	22.74±7.64	24.63±7.42
Biomaterial	0	0	9.99±5.61‡	11.49±2.65‡	37.67±5.59‡	37.79±4.34‡
Blood vessels	1.83±0.89	1.43±0.60	1.03±0.41	0.99±0.54	1.02±0.29	1.08±0.22

Statistically significant intergroup difference: $P<0.05$ (*), $P<0.001$ (†) or $P<0.001$ (‡).

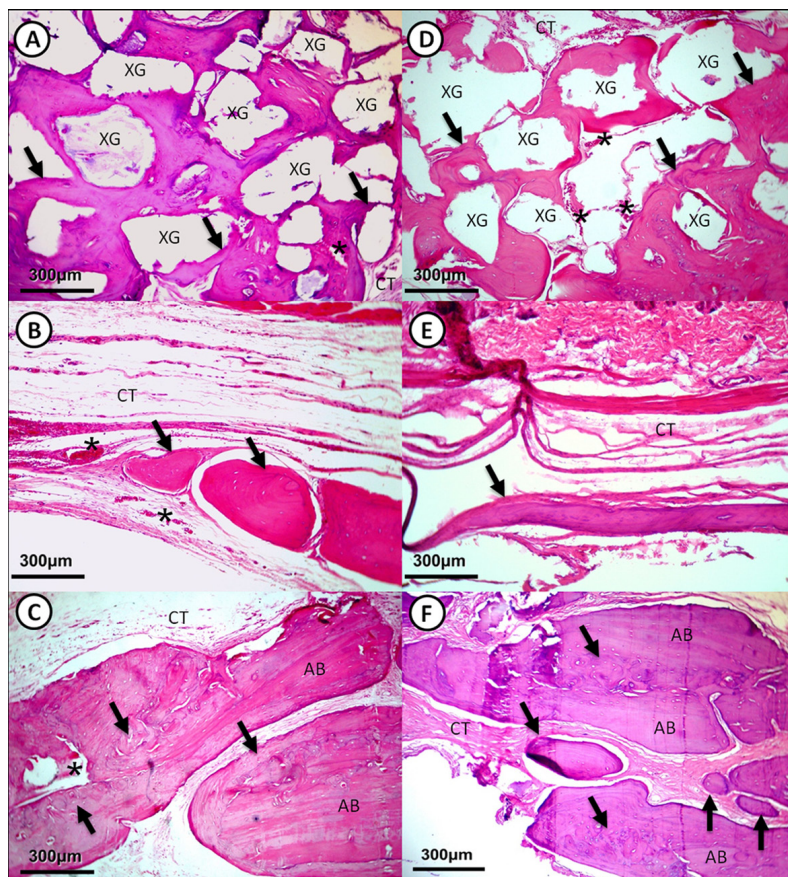


Fig. 5. Bone repair of CSD after 6 months (A-C) and 9 months (D-F). Xenograft/XG particles involved by new bone tissue (arrows) (A,D). Blood clot group presenting bone islets of different sizes (arrows) (B,E). Autogenous bone/AB surrounded and intercalated by new bone tissue (arrows) (C,F). CT: connective tissue, asterisks: blood vessels.

Discussion

Physicochemical processing applied to natural grafts usually preserves only their organic constitution [14]. In the present study, the Brazilian bovine xenograft Extra Graft XG13[®] in XRD analysis showed a mineral phase corresponding to the diffraction pattern of the crystalline hydroxyapatite found in bone, detected in typical intense peaks at 31.77°, 32.19° e 32.90° [15], besides the composition of the organic phase confirmed by FTIR method. FTIR spectrum analysis showed characteristic bands of the collagen molecule and calcium phosphate/hydroxyapatite. The presence of bands 3063 cm⁻¹ (amide B; C-H), 1650 cm⁻¹ (amide I; C=O), 1540 cm⁻¹ (amide II; N-H) and 1230 cm⁻¹ (amide III; C-N) indicate the composition of polypeptide chains present in collagen fibers [16]. The vibration of pyrrolidinic rings of hydroxyproline on the band 1450 cm⁻¹ specifies the existence of type I collagen in the test material, as well as found in the human tissue bone [10]. FTIR spectrum of anorganic portion is evidenced by bands in the region 500-1200 cm⁻¹, in special PO₄³⁻ groups at 560 cm⁻¹, 604 cm⁻¹ (PO₄³⁻, γ 4), 961 cm⁻¹ (PO₄³⁻, γ 1) and 1030 cm⁻¹ (PO₄³⁻, γ 3), besides the bands 873 cm⁻¹, 1420 cm⁻¹ [15,17,18] and 1450 cm⁻¹, this last one related to substitution of PO₄³⁻ group for CO₃²⁻ group [15]. Presence of PO₄³⁻ and CO₃²⁻ groups indicate formation of type B carbonated and consequently calcium-deficient hydroxyapatite, similar to biological apatite found in bone tissue [17]. Based on this, physicochemical processing applied to xenograft maintained the organic composition and similar aspects to mineralized bone matrix, giving a biomimetic property for this bone substitute material.

Initial cell culture tests of this xenograft performed here presented positive results. Indirect contact with the material did not affect the viability of animal cells, presenting a similar behavior observed at the negative control/titanium [14]. Direct contact on the xenograft, with suitable topography and three-dimensional structure, promoted cell adhesion, spreading and proliferation [11], which are important previous steps for the formation of mineralization nodules [5]. Xenograft in short-term *in vivo* experimentation using rat subcutaneous model did not induce an immune-specific response or an exacerbation of innate immunity [7,18], with a similar biological behavior observed at the positive control (hydroxyapatite).

The normal bone repair of CSD varies from 7.6% in 8 weeks to 21.1% in 12 weeks [3]. The use of biomaterials improves the bone repair rate, from 15.8% to 40% in 8 weeks [3] and from 24% to 53.54% in 12 weeks [3,19]. Few long-term results in 6 months point to bone mass increase from 27.2% to 32% even with the use of a highly crystalline hydroxyapatite [19] or up to 59.8% when associated to a pool of bone morphogenetic proteins [20]. Thus, the osteoconductive performance of the xenograft tested was satisfactory. Conversely, the xenograft did not demonstrate good degradability, based on the absence of statistical significance between the different experimental

periods, which could be explained by the fact that this is a highly crystalline material. Several authors reported the importance of the resorption of the biomaterials over time, with a complete replacement by new bone [21]. However, some studies show that this phenomenon is not always present or only a partial resorption of biomaterials is observed [22], nevertheless the new bone formation is not inhibited [19], such as the result of the hydroxyapatite/collagen material used in the present work.

The effectiveness and efficiency of the xenograft based in hydroxyapatite and collagen in relation to new bone formation was similar to autograft, therefore being a promising material for clinical uses. Corroborating our study, maxillary sinus lifting in rabbits showed the same pattern, although the newly formed bone using xenograft was more mature than in the autogenous group [23]. When a demineralized xenograft was used, the autograft induced a higher bone formation, which can be explained by rapid resorption of xenograft impairing bone repair [24]. In alveolar bone defects, resorbable biomaterials are often used expecting its replacement by new bone [22]. Despite the high crystallinity of the material particles that difficult their resorption, the xenograft is indicated for oral surgeries that do not require its complete degradation, providing a framework structure for a longer period. This fact is related to the higher resorption of the autogenous bone over long periods and the replacement of its former space by other cells not related to bone repair such as muscle tissue, fat and skin, as verified in this study.

Brazilian biotechnology industry have developed biomaterials that fulfill the requirements for an effective bone therapy [2,3,6-10,14,15,18,19,21-25]. However, studies in animals cannot be extrapolated to humans. Clinical research in the field of implant dentistry that involves the use of xenografts should discuss more extensively the criteria for functional evaluation, due to the need to assess the real ability of osseointegration and the impossibility to histopathologically detect the implant-xenograft-bone interface after its installation [25]. Therefore, double-blind controlled clinical trials in humans are still needed.

Conclusions

The hydroxyapatite/collagen-based bovine xenograft is non-toxic, biocompatible, osteoconductive and non-resorbable. Due to its structural, short- and long-term biological properties, the tested material comprises a promising bone substitute when compared to autogenous bone for bone loss therapy.

Acknowledgements

This study was supported by a grant-in-aid from the Rio de Janeiro State Research Foundation (FAPERJ, announcement CNE/2006-2009), Financier of Studies and Projects of the Ministry of Science, Technology and Innovation (FINEP-MCT, protocol #01.05.0972.03/2005-2012) and research postgraduate scholarship granted by the Brazilian Government Research Funding Agency (CAPES). Thanks to Silvestre Labs by xenograft donation. The authors are indebted to Prof. PhD. Eliane Porto Barboza from Fluminense Federal University – Department of Periodontics for her critical commentaries to the present work.



References

1. Castro-Silva II, Zambuzzi WF, Granjeiro JM. Current overview of the use of xenograft in dentistry. *Innov Implant J Biomater Esthet.* 2009;4:70-5.
2. Silva IIC, Pimentel-Soares S, Bittencourt RC, Granjeiro JM. Natural bovine anorganic apatite and collagen presents osteoconductivity and contribute to bone repair of rat calvaria critical size defect. *Key Eng Mater.* 2008; 396-398:249-52.
3. Paulo AO, Castro-Silva II, Oliveira DF, Machado MEL, Bonetti-Filho I, Granjeiro JM. Repair of critical-size defects with autogenous periosteum-derived cells combined with bovine anorganic apatite/collagen: an experimental study in rat calvaria. *Braz Dental J.* 2011;22:322-8.
4. Alexander JW. Bone grafting. *Vet Clin North Am Small Anim Pract.* 1987;17:811-9.
5. Castro-Silva II, Zambuzzi WF, Castro LO, Granjeiro JM. Periosteal-derived cells for bone bioengineering: a promising candidate. *Clin Oral Impl Res.* 2012;23:1238-42.
6. Ferreira GR, Cestari TM, Granjeiro JM, Taga R. Lack of repair of rat skull critical size defect treated with bovine morphometric protein bound to microgranular bioabsorbable hydroxyapatite. *Braz Dent J.* 2004;15: 175-80.
7. Galia CR, Macedo CA, Rosito R, Mello TM, Camargo LM, Moreira LF. In vitro and *in vivo* evaluation of lyophilized bovine bone biocompatibility. *Clinics.* 2008;63:801-6.
8. Conz MB, Granjeiro JM, Soares GA. Physicochemical characterization of six commercial hydroxyapatites for medical-dental applications as bone graft. *J Appl Oral Sci.* 2005;13:136-40.
9. Rodrigues CVM, Serricella P, Linhares AB, Guerdes RM, Borojevic R, Rossi AM et al. Characterization of a bovine collagen-hydroxyapatite composite scaffold for bone tissue engineering. *Biomaterials.* 2003;24:4987-97.
10. Sena LA, Caraballo MM, Rossi AM, Soares GA. Synthesis and characterization of biocomposites with different hydroxyapatite-collagen ratios. *J Mater Sci Mater Med.* 2009;20:2395-400.
11. Yuan H, Kurashina K, de Bruijn JD, Li Y, de GK, Zhang X. A preliminary study on osteoinduction of two kinds of calcium phosphate ceramics. *Biomaterials.* 1999;20:1799-806.
12. Granjeiro JM, Oliveira RC, Bustos-Valenzuela JC, Sogayar MC, Taga R. Bone morphogenetic proteins: from structure to clinical use. *Braz J Med Biol Res.* 2005;38:1463-73.
13. Balduino A, Hurtado SP, Frazão P, Takiya CM, Alves LM, Nasciutti LE et al. Bone marrow subendosteal microenvironment harbours functionally distinct haemosupportive stromal cell populations. *Cell Tissue Res.* 2005;319:255-66.
14. Takamori ER, Figueira EA, Taga R, Sogayar MC, Granjeiro JM. Evaluation of the cytocompatibility of mixed bovine bone. *Braz Dent J.* 2007;18:179-84.
15. Accorsi-Mendonça T, Conz MB, Barros TC, de Sena LA, Soares GA, Granjeiro JM. Physicochemical characterization of two deproteinized bovine xenografts. *Braz Oral Res.* 2008;22:5-10.
16. Liu Y, Kim YK, Dai L, Li N, Khan SO, Pashley DH et al. Hierarchical and non-hierarchical mineralization of collagen. *Biomaterials.* 2011;32:1291-300.
17. Wopenka B, Pasteris JD. A mineralogical perspective on the apatite in bone. *Mater Sci Eng C.* 2005;25:131-43.
18. Jardelino CL, Takamori ER, Santos SRA, Rossi AM, Granjeiro JM. Biocompatibility of bovine anorganic xenograft. *Key Eng Mater.* 2008; 396-398:3-6.
19. Conz MB, Granjeiro JM, Soares GA. Hydroxyapatite crystallinity does not affect the repair of critical size bone defects. *J Appl Oral Sci.* 2011;19: 337-42.
20. Sanches RS, Oliveira RC, Zambuzzi WF, Takamori ER, Cestari TM, Taga R et al. Histomorphometric and radiographic monitoring the repair of critical defects in skulls of rats completed with combination of medullary bovine bone plus BMP. *Innov Implant J Biomater Esthet.* 2009;4:32-8.
21. Calasans-Maia MD, Ascoli FO, Novellino ATNA, Rossi AM, Granjeiro JM. Comparative histological evaluation of tibial bone repair in rabbits treated with xenografts. *Acta Ortop Bras.* 2009;17:340-3.
22. Gonçalves F, Hohn A, Granjeiro JM, Silva IIC, Taga R, Cestari TM et al. Bone regeneration in Dentistry with use of composed bone substitute Gen Mix. *Implant News.* 2009;6:373-9.
23. Sicca CM, Corotti MV, Sgarbosa SH, Cestari TM, Cavalcanti MG, Ferreira PM et al. Comparative histomorphometric and tomographic analysis of maxillary sinus floor augmentation in rabbits using autografts and xenografts. *J Biomed Mater Res B Appl Biomater.* 2008;86:188-96.
24. Oliveira RC, Oliveira FH, Cestari TM, Taga R, Granjeiro JM. Morphometric evaluation of the repair of critical-size defects using demineralized bovine bone and autogenous bone grafts in rat calvaria. *Clin Oral Implants Res.* 2008;19:749-54.
25. Abila M, Wuo AV, Bastos F, Tucci R, Tsukumo R, Lima AD. Split-mouth design for biomaterial and autogenous bone combinations in sinus lifting procedures: a case report with histological evaluation. *Implant News* 2009;6:561-6.

