

Differential diagnosis of a salivary gland bone defect by means of computerized tomography: A case report

Diagnóstico diferencial de defeito ósseo mandibular por meio de tomografia computadorizada: Relato de caso

Abstract

Purpose: Salivary gland bone defects are rare entities, generally asymptomatic and found in routine imaging exams. This paper reports the use of computed tomography (CT) with tridimensional rendering to investigate the differential diagnosis of a unilateral radiolucent area located near the angle of the left mandible, below the mandibular dental nerve canal.

Case Description: A 71-year-old Caucasian male subject attended the University Dental Clinics of the Portuguese Catholic University, in Viseu, Portugal, seeking routine dental treatment for oral rehabilitation. Radiographic examination showed a radiolucent unilocular image, well circumscribed, located in the horizontal ramus of the left side of the mandible, near its angle, below the mandibular dental nerve canal. No teeth contact to the radiolucent image was detected. In the panoramic digital radiograph the image had 12 mm mesio-distal width. A CT scan with tridimensional rendering was performed to refine the measurements of the lesion dimension and its relation with other anatomical structures.

Conclusion: According to the clinical and radiographic findings and based on the dental literature, it was concluded that the observed bone cavity was a Stafne bone defect, located in the angle of the mandible below the mandibular dental nerve canal.

Key words: Bone defect; CT scan; mandibular dental nerve; salivary gland; Stafne bone cavity

Resumo

Objetivo: Os defeitos ósseos das glândulas salivares são entidades raras, geralmente assintomáticas e normalmente encontradas em imagiologia de rotina. Neste caso clínico foi utilizada tomografia computadorizada com reconstrução tridimensional para estabelecer o diagnóstico diferencial de uma área radiolúcida unilateral, localizada perto do ângulo mandibular esquerdo, abaixo do canal dentário inferior.

Descrição do Caso: Indivíduo do sexo masculino, 71 anos de idade, raça caucasiana, recorreu à Clínica Odontológica da Universidade Católica Portuguesa, para tratamento dentário. Na radiografia panorâmica foi detectada uma imagem radiolúcida, localizada na região posterior da mandíbula perto do seu ângulo, de limites bem definidos, unilocular, sem contacto com as raízes dentárias, abaixo do canal dentário. Na ortopantomografia digital a imagem media 12 mm méso-distalmente. Utilizou-se uma tomografia computadorizada da mandíbula com reconstrução tridimensional para esclarecer dúvidas relacionadas com as dimensões da imagem e sua relação com estruturas anatómicas vizinhas.

Conclusão: Os exames físico e imagiológicos realizados, juntamente com a revisão de literatura, permitiram concluir que havia um defeito ósseo no ramo horizontal no lado esquerdo da mandíbula, abaixo do canal dentário inferior.

Palavras-chave: Defeito ósseo; Tomografia Assistida por Computador; nervo dentário inferior; glândula salivar; cavidade óssea de Stafne

Filipe Araújo^a
Tiago Marques^b
André Correia^c
António Silva^d
João Tinoco^e

^a Instructor of Fixed Prosthodontics, Master Program of Integrated Dental Medicine, Portuguese Catholic University, Viseu, Portugal

^b Instructor of Periodontology, Master Program of Integrated Dental Medicine, Portuguese Catholic University, Viseu, Portugal

^c Head of Dental Informatics, Master Program of Integrated Dental Medicine, Portuguese Catholic University, Viseu, Portugal

^d Head of Oral Surgery, Master Program of Integrated Dental Medicine, Portuguese Catholic University, Viseu, Portugal

^e Head of Oral Medicine and Oncologic Pathology, Master Program of Integrated Dental Medicine, Portuguese Catholic University, Viseu, Portugal

Correspondence:

Filipe Miguel Araújo
Health and Science Department
Fixed Prosthodontics, Gabinete 7G
Portuguese Catholic University
Estrada da Circunvalação
Viseu, Portugal
3504-505
E-mail: fmiguel.araujo@gmail.com

Received: October 16, 2008
Accepted: December 10, 2008

Introduction

In 1942, Edward Stafne described the clinical presentation of 35 typical bone cavities near the mandibular angle. Those cavities were usually elliptical-shaped, unilocular, radiolucent, and located in the lingual mandibular surface, below the mandibular alveolar nerve, between the first molar and the angle of the mandible (1-4). Rare cases of bilocular defect and bilateral presentation were also reported (1-4). Several terms have been used in the literature to refer to this abnormality: aberrant or ectopic salivary gland defect, static bone defect or cavity, idiopathic bone cavity, Stafne bone cyst, latent bone cyst, lingual mandibular bone depression, and developmental bone defect (4-7). It occurs most frequently in middle aged and older men with an incidence of 4:1000 adults. It is usually asymptomatic and detected in routine maxillofacial radiology (1,2,4,5). If pain is present, other oral pathologies should be considered for differential diagnosis, such as pleomorphic adenoma or chronic sialadenitis (8).

The etiology and pathogenesis of this bone defect remain uncertain. The bone cavity is anatomically related to the submandibular gland fossae and it may contain a portion of salivary gland, adipose tissue, pleomorphic adenoma, connective tissue, lymphoid tissue, striated muscle or blood vessels. In some cases, the cavity is just empty (1-4). Computed tomography (CT) performed parallel to the horizontal axis of the mandibular ramus is an excellent method to demonstrate the imaging features of this entity (1-8). Axial sections of CT or magnetic resonance imaging (MRI), complemented by sialography, are efficient methods for the diagnosis of Stafne bone defects (3).

The present clinical case aimed to report the diagnosis of a unilateral radiolucent area located near the angle of the left mandible, below the inferior dental nerve canal, by means of computerized tomography with tridimensional rendering.

Case Description

A Caucasian, 71 year-old, male subject attended the University Clinics of the Portuguese Catholic University, in Viseu, Portugal, seeking for routine dental treatment for oral rehabilitation. The patient's medical history did not reveal any significant systemic abnormality, and intraoral examination showed a bilateral, linear white line (*linea alba*) in the buccal mucosa, dental caries, and chronic periodontitis. Palpation of cervical and facial lymphatic nodes was asymptomatic.

The digital orthopantomogram (Dimax Planmeca® Oy, Helsinki, Finland) showed a radiolucent image, well circumscribed (12 mm in the mesio-distal diameter), located in the left posterior region of the mandible, near the mandibular angle, below the inferior dental nerve and with no contact with teeth (Fig. 1).

A CT scan was performed with the multislice CT Toshiba® Aquilion S16 (ToshibaEurope Medical System) (sixteen 1 mm-thick slices), at the S. Teotónio Hospital (Viseu, Portugal), to study the dimensions, nature, and relation of the entity with anatomical structures (Fig. 2). A 3D rendering of the mandible was accomplished by using the software eFilm Workstation v.2.1.2® (MERGE Healthcare, Nuenen, Netherlands) (Fig. 3).

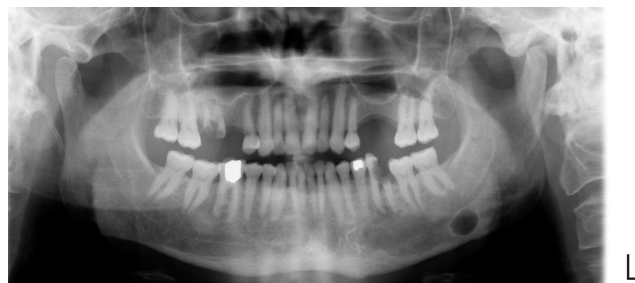

Fig. 1. Panoramic image.

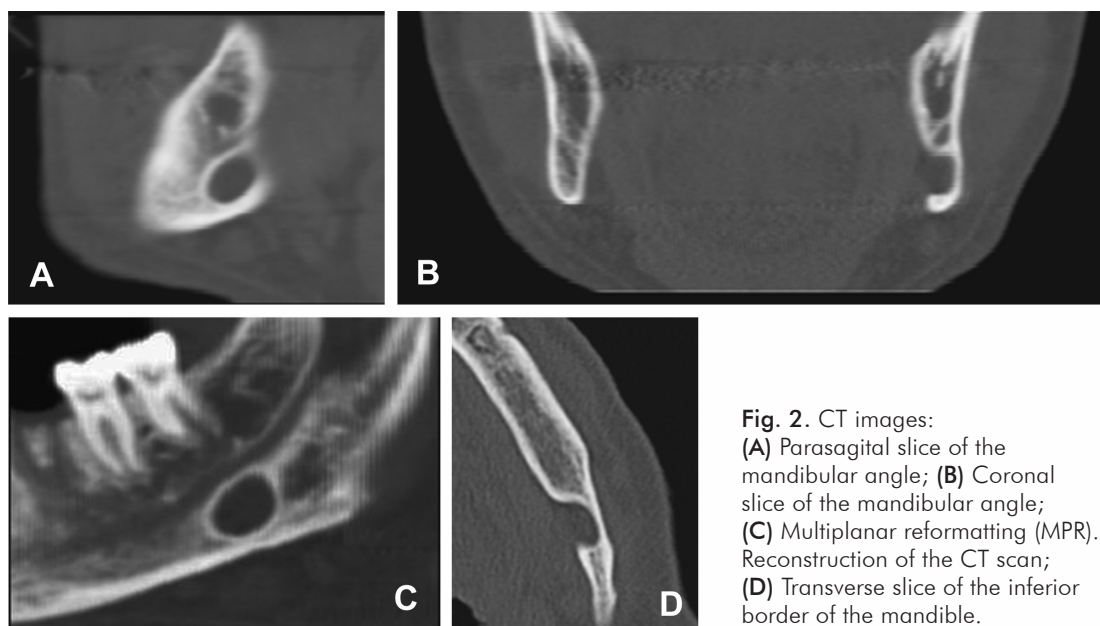


Fig. 2. CT images: (A) Parasagittal slice of the mandibular angle; (B) Coronal slice of the mandibular angle; (C) Multiplanar reformatting (MPR). Reconstruction of the CT scan; (D) Transverse slice of the inferior border of the mandible.

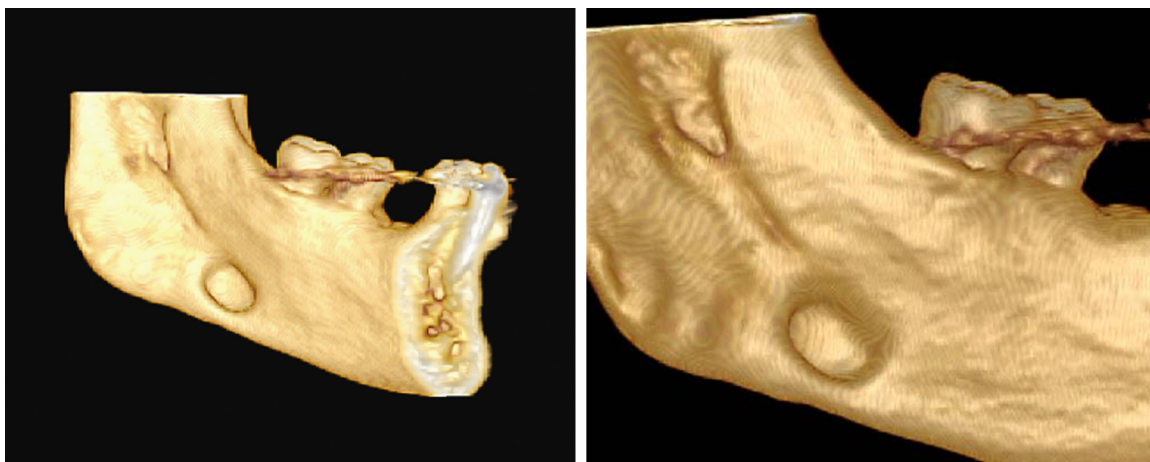


Fig. 3. 3D reconstruction of the mandible (left) and detailed image of the Stafne bone defect (right).

The unilocular concave image had oval shape with 2-3 cm in diameter. The CT scan analysis confirmed the existence of a well defined cortical bone wall at the mandibular lingual face fused with the cortical bone wall of the buccal side. This feature is critical for the differential diagnosis of Stafne bone defect.

Discussion

This paper reported the use of CT scan to confirm the diagnosis of Stafne bone defect found incidentally during a routine radiology. The entity located in the posterior mandible was asymptomatic, unilateral, oval-shaped, unilocular, and well circumscribed, with 2-3 cm. Because the size of the defects rarely changes, they are considered static lesions (1,2,5,6), and a non-invasive approach based on periodic control exams is the recommended clinical procedure (2,5,8). However, in atypical cases or when diagnostic doubts exist, surgical intervention and histopathologic analysis may be indicated to exclude a neoplastic pathology (e.g., pleomorphic adenoma) (2-4). A key anatomic feature of Stafne bone defect is that the mandibular concavity always is open on its lingual face

and the mandibular bone cortical is not compromised. Because this characteristic cannot be seen in a standard orthopantomogram, CT scan is considered an excellent method for the differential diagnosis of Stafne bone defect and/or related pathologies. When compared with surgical intervention, CT scan has a better cost-benefit for the patients and may be required before interventions in the affected area for oral rehabilitation.

Although Stafne bone defects are considered static lesions and do not require any intervention, periodic clinical examination and radiograph follow-up are advisable.

Acknowledgments

The authors would like to thank Professor Joaquim Agostinho, MD, Department of Imagiology in the Master of Integrated Dental Medicine of the Portuguese Catholic University, and Professor Miguel Costa, DDM, Department of Oral Medicine and Oncologic Pathology in the Master of Integrated Dental Medicine of the Portuguese Catholic University, for their valuable help in this diagnostic image research.

References

1. Apruzzese D, Longoni S. Stafne cyst in an anterior location. *J Oral Maxillofac Surg* 1999;57:333-8.
2. Katz J, Chaushu G, Rotstein I. Stafne's bone cavity in the anterior mandible: a possible diagnostic challenge. *J Endod* 2001;27:304-7.
3. Segev Y, Puterman M, Bodner L. Stafne bone cavity-magnetic resonance imaging. *Med Oral Patol Oral Cir Bucal* 2006;11: E345-7.
4. White, SC, Pharoah MJ. Developmental disturbances of the face and jaws. *Oral Radiology. Principles and Interpretation*. 4. ed. Mosby; 2000. p. 598-600.
5. Quesada-Gómez C, Valmaseda-Castellón E, Berini-Aytés L, Gay-Escoda C. Stafne bone cavity: a retrospective study of 11 cases. *Med Oral Patol Oral Cir Bucal* 2006;11:E277-80.
6. Shimizu M, Osa N, Okamura K, Yoshiura K. CT analysis of the Stafne's bone defects of the mandible. *Dentomaxillofac Radiol* 2006;35:95-102.
7. Slasky BS, Bar-Ziv J. Lingual mandibular bony defects: CT in the buccolingual plane. *J Comput Assist Tomogr* 1996;20:439-43.
8. Ariji E, Fujiwara N, Tabata O, Nakayama E, Kanda S, Shiratsuchi Y, Oka M. Stafne's bone cavity. Classification based on outline and content determined by computed tomography. *Oral Surg Oral Med Oral Pathol* 1993;76:375-80.