

Endodontic treatment of dental formation anomalies

Tratamento endodôntico de anomalia dental de formação

Abstract

Purpose: Dental fusion is defined as the union of two dental germs at some stage of their development. The aim of this article is to report the endodontic treatment of two clinical cases of dental fusion.

Case description: In the first case, the patient was referred by an orthodontist for endodontic treatment of tooth 12, which was fused to 13. Surgical separation and later replacement of the involved elements in the dental arch was indicated. In the second case, the patient sought dental attendance due to spontaneous pain. In the radiographic exam, gemination in tooth 11 and fusion of 21 with a supernumerary tooth was observed. The fused teeth were endodontically treated, and patients were referred to other dental specialties to reestablish esthetics and function.

Conclusion: The dentist must be able to diagnose, differentiate and treat these dental anomalies adequately, with the goal of maintaining patients' oral health.

Key words: Diagnosis, differential; dental pulp; Endodontics; fused teeth; tooth, supernumerary

Resumo

Objetivo: Fusão dental é definida como sendo a união de dois germes dentais em algum momento do estágio de desenvolvimento. O objetivo desse artigo foi descrever o tratamento endodôntico de dois casos de fusão dental.

Descrição do caso: No primeiro caso clínico, o paciente foi orientado pelo ortodontista a realizar tratamento endodôntico do dente 12, o qual estava fusionado ao dente 13. Foi realizada a separação cirúrgica dos elementos dentais e posterior reposicionamento no arco dental. No segundo caso clínico, o paciente procurou atendimento relatando dor espontânea na região anterior superior. Por meio do exame radiográfico, foi observado geminação do dente 11 e fusão do dente 21 com dente extranumerário. Em ambos os casos os dentes fusionados foram tratados endodônticamente e os pacientes encaminhados para restabelecimento da estética e função.

Conclusão: O cirurgião dentista deve ter habilidade de diagnosticar, diferenciar e tratar adequadamente as anomalias dentárias, objetivando a manutenção da saúde oral dos pacientes.

Palavras-chave: Diagnóstico diferencial; dentes fusionados; Endodontia; polpa dentária; dente supranumerário

Maria Isabel Anastacio Faria ^a
Alvaro Henrique Borges ^{a,b}
Sérgio Murilo Carneiro ^a
João Manoel Silva Filho ^a
Alex Semenov Segundo ^b
Antônio Miranda da Cruz Filho ^c

^a Stricto Sensu Program - Doctoral Level, University of Ribeirão Preto, Ribeirão Preto, SP, Brazil

^b Department of Endodontics, Dental School, University of Cuiabá, Cuiabá, MT, Brazil

^c Department of Restorative Dentistry, Dental School of Ribeirão Preto, University of São Paulo, Ribeirão Preto, SP, Brazil

Correspondence:

Maria Isabel Anastacio Faria
Rua Visconde de Nacar 865, cj. 1007
Curitiba, PR – Brazil
80410-904
E-mail: mariaisabelfaria@ufpr.br

Received: April 10, 2010
Accepted: January 28, 2011

Conflict of Interest Statement: The authors state that there are no financial and personal conflicts of interest that could have inappropriately influenced their work.

Copyright: © 2011 Faria et al.; licensee EDIPUCRS. This is an Open Access article distributed under the terms of the Creative Commons Attribution-Noncommercial-No Derivative Works 3.0 Unported License.

Introduction

Tooth formation anomalies are rare disturbances, which are capable of originating dental elements with very unusual anatomy (1). These anatomic changes can occur in the tooth crown, root and root canal (2). Gemination and fusion are developmental anomalies of hard tissues with close similarity inherited by different aetiology (2). In cases of fusion, the crowns are united by enamel and/or dentin, but there are two roots or two root canals in a single root. It has been suggested that there may be fusion between the teeth of the normal series or between one of the normal series and a supernumerary tooth (3). Dental fusion is characterized by the union of two dental germs during the developmental stage, in consequence of aberration of both the ectoderm and mesoderm (3,4). It is mainly observed in deciduous dentition (5), which may be complete or incomplete, depending on the stage of development in which the union occurred (6). The incidence is greater in incisors and canines with apparent equal distribution between the two jaws, and cases involving molar teeth are rare (7,8). It is more common in the anterior region, approximately 0.1% occurs in permanent and 0.5%

in primary dentition, with an equal distribution in females and males, among Caucasians (9).

The etiology of this type of anomaly is unknown. Some authors believe that there is a physical force that approaches and causes contact between the dental germs, leading to necrosis of the epithelium that separates them, causing fusion (10). Fused teeth are normally more susceptible to caries and periodontal problems because they present a large number of scratches and gaps at the site of the junction (11). These gaps may be located subgingivally, being a bacterial plaque accumulation site, and could cause misalignment of the adjacent teeth (12).

The aim of this study was to describe two cases of successful endodontic treatment in anterior teeth with fusion/gemination anomalies.

Description of the cases

Case 1

The patient, a 13-year-old girl, was referred by the orthodontist for endodontic treatment of the right lateral maxillary incisor. In a clinical exam, it was observed that the tooth in question presented the clinical crown enlarged (Fig. 1A and 1B). The radiographic exam showed the presence of two pulp chambers and two root canals. Fusion of elements 12 and 13 was found (Fig. 2 A). Both teeth responded positively to the pulp vitality test (Endo Ice, Hygenic, Akron, OH, USA). Radical endodontic therapy of the teeth involved was performed, so that the teeth could later be surgically separated and repositioned in the dental arch.

After coronal opening and access to the root canals, cleaning and shaping was achieved using stainless steel K Files up to instrument type K (Dentsply Maillefer, Ballaigues, Switzerland) 70 size (ISO 0.02 taper) and irrigation with 1% sodium hypochlorite was performed. When preparation was completed, the teeth were irrigated with 17% EDTA and dried with absorbent paper cones; obturation was done using zinc oxide and eugenol-

based cement with gutta-percha (Dentsply Maillefer, Ballaigues, Switzerland) by Tagger's hybrid technique (Fig. 2 B). The coronal access was sealed with zinc phosphate cement. Unfortunately, the patient did not return for the tooth restoration and follow-up.

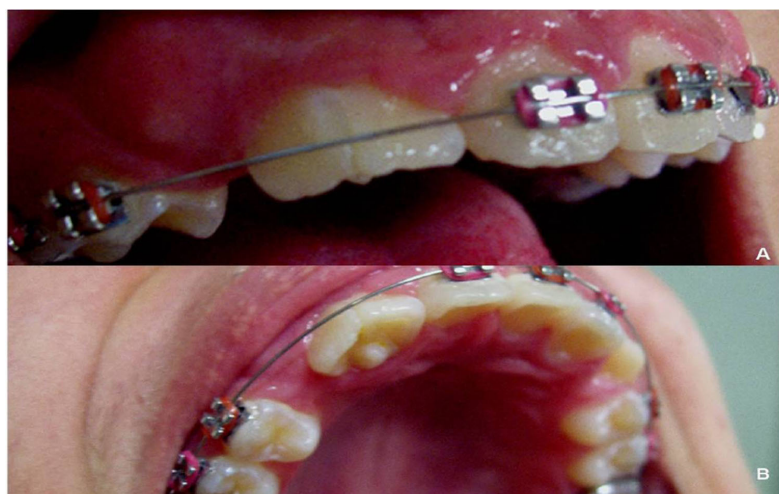

Fig. 1. Clinical view. A) Vestibular view of fused crown of tooth 12 and 13. B) Lingual view.

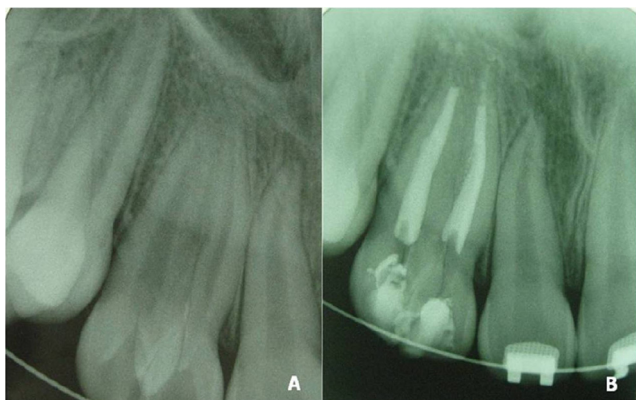


Fig. 2. A) The initial radiographic: fusion of elements 12 and 13 was found. B) Endodontic treatment completed.

Case 2

The patient, a 12-year old boy, presented spontaneous pain in the antero-maxillary region. Generalized gingivitis was observed. During periodontal probe exam, no bone loss was found around the anterior teeth and there was no presence of exsudate or fistular trajectory. Clinical (Fig. 3A and 3B) and radiographic exams showed the extensive pulp chamber of element 21 (Fig. 4A), with indication of an attempt to separate and a single canal, suggesting gemination. There was also fusion between the element 11 and a supernumerary tooth, resulting in an element with an extensive pulp chamber and presence of two root canals (Fig. 4B).

Pulp vitality test was performed. In tooth 21, thermal test was positive to cold (Endo Ice, Hygenic, Akron, OH, USA), and there was no clinical or radiographic alteration (Fig. 4A). Tooth 11 presented caries lesion in the distal region and positive vitality test to cold. After removing the carious tissue

there was exposure of the pulp tissue and consequent radical endodontic treatment. The work length was determined (Fig. 4C) and biomechanical preparation up to instrument type K (Dentsply Maillefer, Ballaigues, Switzerland) 60 size (ISO 0.02 taper) and irrigation with 1% hypochlorite sodium was performed. Obturation was performed using Tagger's hybrid technique with an inverted cone 60 size (Fig. 4D) (Dentsply Maillefer, Ballaigues, Switzerland) and zinc oxide and eugenol-based cement (Fig. 4E). The follow-up 5 years later confirmed the periapical health of the treated dental element (Fig. 4F).

Discussion

Tooth fusion and gemination are two different anomalies of formation, characterized by the formation of a tooth with a wide clinical crown. Fusion is the union of two dental germs, which may occur at the level of enamel or dentin, depending

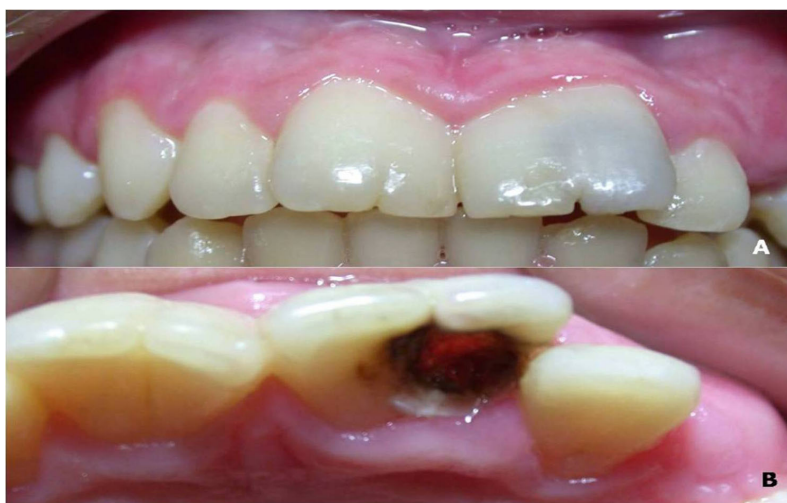
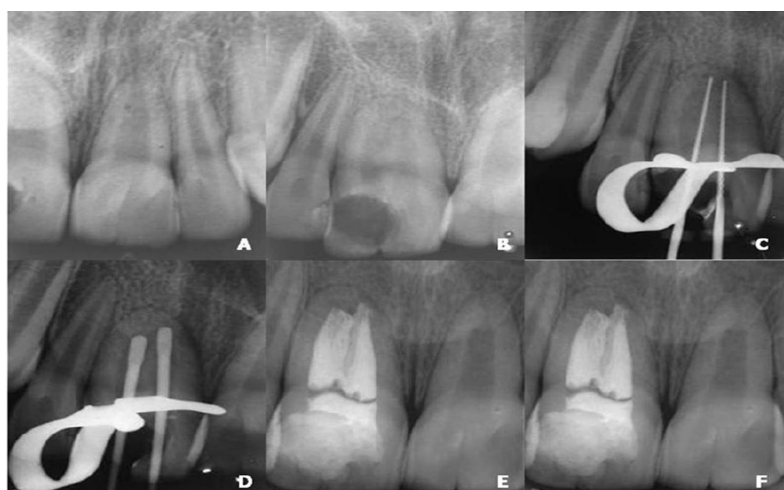
Fig. 3. A) Vestibular view of 11 and 21 large clinical crown. B) Lingual view.

Fig. 4. A) Radiograph showing the extensive pulp chamber of element 21. B) Radiograph showing fusion between the element 11 and a supernumerary tooth, resulting in an element with an extensive pulp chamber and presence of two root canals. C) Radiograph showing the determination of working length. D) Radiograph of cone proof with an inverted-cone. E) Radiograph of final obturation. F) Radiograph of the 5-year follow-up.



on the developmental stage of the germs. Clinically, the fused tooth presents a large clinical crown and when seen radiographically, it has one or two pulp chambers and two root canals (13). This situation was observed in teeth 12 and 21 of the first and second clinical cases, respectively. Gemination, observed in tooth 21 of the second clinical case discussed, was an attempt to divide a dental germ. The tooth presented a wide clinical crown and when seen radiographically, there were two pulp chambers and only one root canal (2).

In spite of several reports in the literature about the subject, differential diagnosis between these two anomalies becomes difficult when fusion occurs between a tooth in the arch and a supernumerary tooth (9,14), as occurred with the second case discussed. When fusion occurs between two regular teeth in the arch, it is easily differentiated from germination, because there are fewer teeth in total. Therefore, the case history and clinical and radiographic exam are

extremely important for obtaining the correct diagnosis.

Both fusion and germination are more common in anterior teeth and rarely occur in posterior teeth. The affected teeth normally present esthetic problems. Indra et al. (5) emphasized that the anomaly of these teeth is unusual, but Tsesis et al. (2) reported that fused teeth are asymptomatic and do not require treatment unless they interfere with the patient's occlusion or esthetic appearance. Kim and Jou (15) reported that surgical division and orthodontic replacement of these teeth may be necessary and emphasized the importance of and need for multidisciplinary treatment.

The dentist must be alert when faced with cases of teeth that present anomalies due to the differentiated morphology of dental crowns and roots. Although the incidence of these cases of dental fusion in the dental office is not common, the dentist must be able to diagnose, differentiate and treat them adequately, with the goal of maintaining patients' oral health.

References

1. Veeraiyan DN, Fenton A. Dental fusion: A case report of esthetic conservative management. *Quintessence Int* 2009;40:801-3.
2. Tsesis I, Steinbock N, Rosenberg E, Kaufman AY. Endodontic treatment of developmental anomalies in posterior teeth: treatment of geminated/fused teeth – report of two cases. *Int Endod J* 2003;36:372-9.
3. Yucel AC, Guler E. Nonsurgical endodontic retreatment of geminate teeth: a case report. *J Endod* 2006;32:1214-6.
4. Danesh G, Schrijnemakers T, Lippold C, Schäfer E. Fused maxillary central incisor with dens evaginatus as a talon cusp. *Angle Orthod* 2006;77:176-80.
5. Indra R, Srinivasan MR, Farzana H, Karthikeyan K. Endodontic management of a fused maxillary lateral incisor with a supernumerary tooth: a case report. *J Endod* 2006;32:1217-9.
6. Chalakkal P, Thomas AM. Bilateral fusion of mandibular primary teeth. *J Indian Soc Pedod Prevent Dent* 2009;27:108-10.
7. Nunes E, Moraes IG, Novaes PMO, Sousa SMG. Bilateral fusion of mandibular second molars with supernumerary teeth: case report. *Braz Dent J* 2002;13:137-41.
8. Liu S, Fan B, Peng B, Fan M, Bian Z. Endodontic treatment of an unusual connotation of permanent mandibular molars: a case report. *Oral Surg Oral Med Oral Pathol Oral Radiol Endod* 2006;102:e72-7.
9. Ghoddusi J, Zarei M, Jafarzadeh H. Endodontic treatment of a supernumerary tooth fused to a mandibular second molar: a case report. *J Oral Sci* 2006;48:39-41.
10. Tumen EC, Hamamci N, Kaya FA, Tumen DS, Çelenk S. Bilateral twinned teeth and multiple supernumerary teeth: a case report. *Quintessence Int* 2008;39:567-72.
11. Siqueira VCF, Braga TL, Martins MAT, Raitz R, Martins MD. Dental fusion and dens evaginatus in the permanent dentition: literature review and clinical case report with conservative treatment. *J Dent Child* 2004;71:69-72.
12. Olivan-Rosas G, Lopez-Jiménez J, Gimenez-Prats MJ, Piqueras-Hernandez M. Consideration and differences in the treatment of a fused tooth. *Med Oral* 2004;9:224-8.
13. Cimilli H, Kartal N. Endodontic treatment of unusual central incisors. *J Endod* 2002;28:480-1.
14. Tuna EB, Yildirim M, Seymen F, Gencay K, Ozgen M. Fused teeth: a review of the treatment options. *J Dent Child* 2009;76:109-16.
15. Kim E, Jou Y. A supernumerary tooth fused to the facial surface of a maxillary permanent central incisor: case report. *J Endod* 2000;28:45-8.