



A rare case of bilateral mandibular simple bone cyst and the importance of differential diagnosis

Saulo Gabriel Moreira Falci^a, Késsia Nara Andrade Sales^b, Lorena Vieira da Silva^b,
Cássio Roberto Rocha dos Santos^c

ABSTRACT

Objective: To present a rare case of a mandibular bilateral simple bone cyst (SBC) with different radiological features and argue about the importance of the differential diagnosis.

Case description: A 16-year-old boy was referred by his dentist to evaluate two radiolucent mandibular lesions. The diagnostic hypotheses were ameloblastoma or keratocystic odontogenic tumor to the left side and odontogenic cyst on the right side due radiologic features. In the left side, needle aspiration and biopsy, were performed. During surgical approach there was an empty space in the surgical cavity compatible with SBC. At this moment the diagnostic was made and the cavity was submitted to rigorous curettage. The right side was assessed after 4 months. To our surprise, it was found an empty cavity, as the left side. Six months later the first biopsy the panoramic radiograph showed completely bone neoformation on both sides. The patient is in radiographic follow-up for three years, without relapse.

Conclusions: Bilateral SBC is a rare condition that can show different radiographic features. The diagnostic is defined at the surgery time. The radiographic features helps in diagnosis, however, should not be decisive. Surgical exploration should be done soon after radiographic diagnoses.

Key words: Bone cyst; Mandible; Curettage; Oral surgery

^a Piracicaba Dental School, State University of Campinas-UNICAMP, Campinas, SP, Brazil.

^b Dental Surgeon

^c School of Dentistry, Federal University of Vales do Jequitinhonha e Mucuri, Diamantina, MG, Brazil

Um caso raro de cisto ósseo simples bilateral e a importância do diagnóstico diferencial

RESUMO

Objetivo: Apresentar um caso raro de cisto ósseo simples (COS) bilateral mandibular com diferentes características radiográficas e discutir sobre a importância do diagnóstico diferencial.

Descrição do caso: Um paciente do sexo masculino de 16 anos foi encaminhado do seu dentista para avaliar duas lesões radiolúcidas mandibulares. As hipóteses diagnósticas foram ameloblastoma ou tumor odontogênico queratocístico no lado esquerdo e cisto odontogênico no lado direito. No lado esquerdo punção aspirativa e biópsia foram realizadas. Durante o acesso cirúrgico foi observada uma cavidade óssea vazia compatível com COS. Nesse momento o foi concluído o diagnóstico e a cavidade foi submetida a curetagem. O lado direito foi investigado depois de 4 meses. Para a nossa surpresa, foi encontrada uma cavidade vazia, como no lado esquerdo. Seis meses após a primeira biópsia a radiografia panorâmica evidenciou completa formação óssea em ambos os lados. O paciente está em acompanhamento radiográfico por três anos, sem recidiva.

Conclusão: COS bilateral é uma condição rara que pode apresentar diferentes características radiográficas. O diagnóstico é definido no momento da cirurgia. As características radiográficas auxiliam no diagnóstico, entretanto, não devem ser decisivas. A exploração cirúrgica deve ser realizada logo após o diagnóstico radiográfico.

Palavras-chave: Cistos ósseos; Mandibular; Curetagem; Cirurgia bucal

Correspondence:
Saulo Gabriel Moreira Falci
saoulfalci@hotmail.com

Received: July 7, 2013
Accepted: April 20, 2017

Conflict of Interests: The authors state that there are no financial and personal conflicts of interest that could have inappropriately influenced their work.

Copyright: © 2016 Falci et al.; licensee EDIPUCRS.

This work is licensed under a Creative Commons Attribution 4.0 International License.



<http://creativecommons.org/licenses/by/4.0/>

INTRODUCTION

Simple bone cyst (SBC) is a non-odontogenic intra-osseous lesion that presents unknown etiology. The most common sites affected are the long bones, with only 10% of the cases in the jaw bones. Mandible is usually affected in the premolar and chin regions [1]. Despite the name, the SBC is not true cystic lesion, because the bone cavity is not usually coated by epithelium [2]. Other names for SBC are described in the literature as, idiopathic bone cavity, traumatic bone cyst and hemorrhagic bone cyst [3].

There are some theories to explain the etiology of the SBC as abnormal bone growth or tumor degeneration and intramedullary hemorrhage. Nowadays, the intramedullary hemorrhage theory is the most widely accepted to explain the etiology. The bone trauma, insufficient to fracture a bone healthy, may induce an intramedullary hemorrhage. The pressure of the hematoma causes venous stasis that promotes necrosis followed by osteoclastic resorption [1]. Some authors still states that this intramedullary hemorrhage may be caused by other factor as previous tooth extraction [4].

In the most of cases, the SBC is asymptomatic and found on routine radiographs [5]. Radiographic examination shows radiolucent lesions, with thin and irregular, but well defined, sclerotic margins [3]. In some cases SBC may have multilocular pattern, usually presenting appearance of “glove fingers” when it extends among the teeth roots [4]. Computed tomography may be helpful in diagnosis, because it allows assessing the intralesional density [6]. However, in most cases, the diagnosis is confirmed at the surgical moment by the presence of the empty cavity. The prognosis is excellent, but it takes a period of monitoring to ensure that the lesion will not relapse [1].

The differential diagnosis between SBC and other maxillary lesions is extremely important because the SBC does not show exclusive clinical and radiographic features. Understanding of clinical and radiographic features is extremely important to the oral and maxillofacial surgeon. Thus, this paper presents a rare case of bilateral mandibular SBC with different radiographic features, suggesting two different lesions.

CASE DESCRIPTION

A 16-year-old boy was referred to the School of Dentistry at the Federal University of Vales do Jequitinhonha e Mucuri, Brazil by his dentist, to evaluate two radiolucent lesions in the lower jaw, viewed on routine panoramic radiograph.

The interview does not reveal systemic symptoms, medication use, and history of trauma to the affected region. There were no reports of pain or swelling and maxillofacial exams showed no changes. The panoramic radiograph showed two lesions, one on the left and other on the right side. The right (between tooth 48 and 47) and left (from tooth 33 to tooth 38) lesions showed unilocular and multilocular

characteristics, respectively. Both of them showed well-defined limits (Fig. 1). The teeth spanning 37 to 33 were vital. The diagnostic hypotheses were ameloblastoma or keratocystic odontogenic tumor to the left side and odontogenic cyst on the right side. Needle aspiration and biopsy were performed under local anesthesia, in the left lesion and, produced a yellowish liquid. During the surgical approach there was an empty space in the surgical cavity compatible with SBC (Fig. 2). At this moment the diagnostic of SBC was made and the cavity was submitted to rigorous curettage. To access the other lesion an arrangement with the patient was made to the following week. However, he did not show for the consultation. After four months the patient came back to the office. At this moment the right third molar was removed and, to our surprise, the approach showed an empty space below the third molar also compatible with SBC (Fig. 3). Six months later first biopsy, the patient has undergone to a new panoramic radiograph that showed completely bone neoformation in both sides (Fig. 4). The patient is in radiographic follow-up for three years, with no signs of clinical and radiographic relapse.

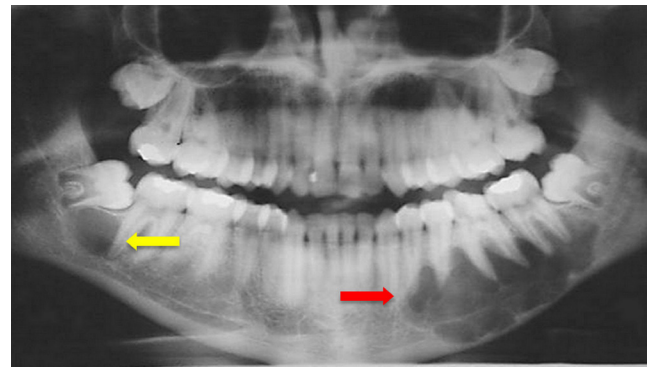


Figure 1. Panoramic radiograph showing the lesions. On the left side, a multilocular lesion with well-defined edges (red arrow) and on the right side, a unilocular lesion (yellow arrow)

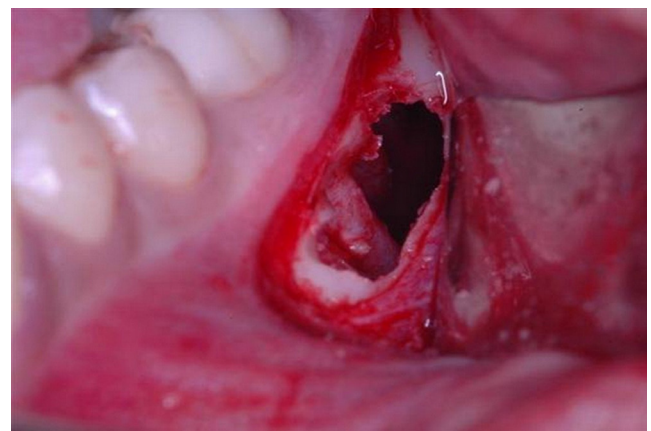


Figure 2. Surgical area after osteotomy of the right side, revealing an empty cavity compatible with simple bone cyst

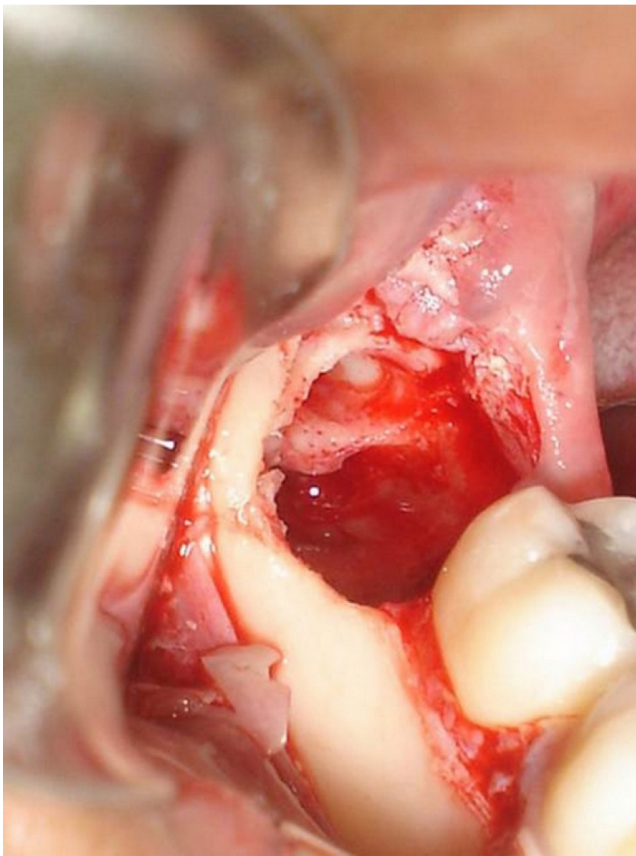


Figure 3. Surgical area after third molar extraction and osteotomy of the left side, where we can see an empty cavity compatible with simple bone cyst

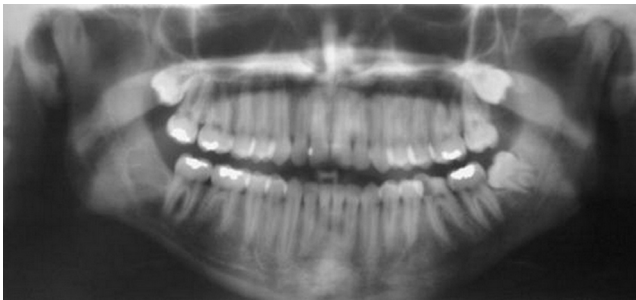

Figure 4. Panoramic radiograph six months after the first surgery showing a new bone formation in both sides

DISCUSSION

The differential diagnosis of SBC may be any radiolucent lesion as, keratocystic odontogenic tumor, ameloblastoma, dentigerous cyst, central giant cell lesion among other [2]. In this case, the distinct radiographic features have induced two different diagnostic hypotheses, ameloblastoma or keratocystic odontogenic tumor to the multilocular lesion and odontogenic cyst to the unilocular lesion. Needle

aspiration reinforced the diagnostic hypothesis for the multilocular lesion. Intra and extra-oral examination were normal, reflecting the potential of the lesion to develop among the marrow spaces. It is normal to see this lesion involving the interdental spaces, but, on the other hand root resorption, mobility, or losses of vitality are not seen [4], as we see in this case.

Treatment of simple bone cyst is usually a surgical exploration with vigorous bone curettage [3]. This procedure reestablishes the bleed inside of lesion, followed by clot reorganization and a bone neoformation due the presence of osteogenic cells [7]. The choice of treatment protocol depends on the radiographic characteristic of the lesion. In this case, the distinct radiographic features resulted in two different treatment plans, incisional biopsy for the left side and excisional biopsy for the right side. This difference was based on the different diagnostic hypothesis. Even with different sizes and radiologic features both lesions were SBC, confirmed by intraoperative finding of an empty space. The occurrence of multiple SBC is rare in the English-language literature, and there are few reported cases, since 1929, when the first case was reported [5].

The most accepted theory for the development of SBC is through of intramedullary hemorrhage with a defect on healing or a clot lysis [1]. However, the etiology remains unclear, because in most of cases there is no clear history of trauma, as in this case. The lack of lymphatic synovial drainage has also proposed as a possible cause, once the interstitial fluid would accumulate in bone trabeculae, leading to hemodynamic disorder and consequently cyst formation [8]. In this case, the lesion development probably occurred due this disorder. This may explain the bilateral occurrence, since the theory of trauma would be more difficult to happen bilaterally. Histologically, bone covered by a thin layer of loose fibrous connective tissue may be seen [1]. However, in this case it was not necessary the histological evaluation, because the definitive diagnosis was made during surgical procedure, due a presence of empty cavity.

The treatment prognosis for SBC is excellent, however is necessary at least three years of radiographic follow up, to notice early evidence of treatment failure or relapse [9,10]. In this case, six months after curettage, new bone formation was observed in both lesions. Thus, after this period the chances of relapse are smaller once that it occurs after three months normally. However, this case is under three years of follow up, as preconized by Swei et al., [9] once this lesion can present slow growth.

SBC is a slow-growing lesion, asymptomatic, found in routine radiograph evaluation in young patients. Bilateral SBC is a rare condition that can show different radiographic features. Diagnostic is defined at the surgery time. The period of follow up should be long enough to prove the success of treatment and treat early any relapse. The radiographic features helps in diagnosis, however, should not be decisive as shown in this case. Thus, surgical exploration and biopsy should be done immediately after radiographic diagnoses.



REFERENCES

1. Harnet JC, Lombardi T, Klewansky P, Rieger J, Tempe MH, Clavert JM. Solitary bone cyst of the jaws: a review of the etiopathogenic hypotheses. *J Oral Maxillofac Surg.* 2008;66:2345-8. <https://doi.org/10.1016/j.joms.2007.08.035>
2. Mupparapu M, Milles M, Singer SR, Rinaggio J. Rare, simultaneous, multiple, and recurrent mandibular bone cysts. *Quintessence Int.* 2008;39:331-6.
3. Cortell-Ballester I, Figueiredo R, Berini-Aytés L, Gay-Escoda C. Traumatic bone cyst: A retrospective study of 21 cases. *Med Oral Patol Oral Cir Bucal.* 2009;14:e239-43.
4. Xanthinaki AA, Choupis KI, Tosios K, Pagkalos VA, Papanikolaou SI. Traumatic bone cyst of the mandible of possible iatrogenic origin: a case report and brief review of the literature. *Head and Face Medicine.* 2006;12:2:40.
5. Kuhmichel A, Bouloux GF. Multifocal Traumatic Bone Cysts: Case Report and Current Thoughts on Etiology. *J Oral Maxillofac Surg* 2010;68:208-12. <https://doi.org/10.1016/j.joms.2009.07.024>
6. Suei Y, Taguchi A, Kurabayashi T, Kobayashi F, Nojiri M, Tanimoto K. Simple bone cyst: investigation on the presence of gas in the cavity using computed tomography – review of 52 cases. *Oral Surg Oral Med Oral Pathol Oral Radiol Endod.* 1998;86:592-4. [https://doi.org/10.1016/S1079-2104\(98\)90352-3](https://doi.org/10.1016/S1079-2104(98)90352-3)
7. Magliocca KR, Edwards SP, Helman JI. Traumatic bone cyst of the condylar region: report of 2 cases. *J Oral Maxillofac Surg.* 2007;65:1247-50. <https://doi.org/10.1016/j.joms.2005.08.026>
8. Cohen J. Simple bone cysts. Studies of cyst fluid in six cases with a theory of pathogenesis. *J Bone Joint Surg Am.* 1960;42:609-16. <https://doi.org/10.2106/00004623-196042040-00005>
9. Suei Y, Taguchi A, Tanimoto K. Simple bone cyst of the jaws: evaluation of treatment outcome by review of 132 cases. *J Oral Maxillofac Surg.* 2007;65:918-23. <https://doi.org/10.1016/j.joms.2006.06.297>
10. De Souza Noronha VR, Sette-Dias AC, Abdo EN, Gomez RS, de Mesquita RA. Asynchronous idiopathic bone cavity: a case report. *J Craniomaxillofac Surg.* 2012;40:e328-30. <https://doi.org/10.1016/j.jcms.2012.02.001>

