



Dental implants in a patient with Paget's disease: a case report

Marcus Azevedo Amaral^a, Aline Semblano Carreira Falcão^b, Mayara Sabrina Luz Miranda^b, Valtuir Barbosa Félix^b, Sérgio de Melo Alves Jr.^b, Maria Sueli da Silva Kataoka^b

Abstract

Objective: Paget's disease (PD) is a metabolic bone disease characterized by increased bone resorption followed by excessive, unregulated bone formation. While its etiology remains elusive, several genetic and environmental factors have been implicated. PD results in weakened bone strength and abnormal bone architecture, which may be unfavorable for the placement of osseointegrated dental implants. Herein, we describe a patient with PD who received dental implants.

Case description: An 86-year-old woman diagnosed with PD and treated with oral bisphosphonates, was referred for implant treatment. Four dental implants were fixed in the anterior mandible, and all implants presented good primary stability. The patient was followed for a period of 6 years. No clinical mobility or signs of loosening were observed, and the implants were successfully osseointegrated.

Conclusion: We conclude that the use of bisphosphonates in PD can be an important role in the insertion and osseointegration of dental implants. However, additional research is needed to confirm these findings.

Key words: Paget's disease; dental implants; bisphosphonates.

^a School of Dentistry, University of São Paulo – USP, SP, Brazil

^b School of Dentistry, Federal University of Pará – UFPA, Belém, PA, Brazil

Implantes dentários em uma paciente com Doença de Paget: relato de caso

Resumo

Objetivo: A doença de Paget (DP) é uma desordem óssea metabólica caracterizada por uma reabsorção óssea aumentada seguida por um excesso de formação de osso não regulada. Embora sua etiologia permaneça indefinida, vários fatores genéticos e ambientais têm sido implicados. A DP resulta em força óssea enfraquecida e arquitetura óssea anormal, que pode ser desfavorável para a colocação de implantes dentários osseointegrados. No presente trabalho, relata-se um caso de uma paciente com DP que recebeu implantes dentários.

Descrição do caso: Uma mulher de 86 anos de idade com diagnóstico de DP e tratada com bisfosfonatos orais foi encaminhada para tratamento com implantes. Quatro implantes dentários foram fixados em região anterior da mandíbula e todos os implantes apresentaram boa estabilidade primária. O acompanhamento clínico da paciente foi feito por um período de 6 anos. Não foram observados mobilidade clínica ou sinais de frouxidão e os implantes foram com sucesso osseointegrados.

Conclusão: Concluímos que o uso de bisfosfonatos na DP pode ter um papel importante na inserção e na integração óssea de implantes dentários. No entanto, pesquisas adicionais são necessárias para confirmar estes resultados.

Palavras-chave: doença de Paget; implantes dentários; bisfosfonatos.

Correspondence:
Maria Sueli da Silva Kataoka
sukataoka@yahoo.com.br

Received: April 18, 2013
Accepted: November 19, 2014

Conflict of Interests: The authors state that there are no financial and personal conflicts of interest that could have inappropriately influenced their work.

Copyright: © 2014 Amaral et al.; licensee EDIPUCRS.

Except where otherwise noted, content of this journal is licensed under a Creative Commons Attribution 4.0 International license.



<http://creativecommons.org/licenses/by/4.0/>

Introduction

Paget's disease is a chronic skeletal disorder that is characterized by areas of osteoclast-mediated increased bone resorption followed by disorderly osteoblast-mediated bone repair [1].

This disorder affects both men and women, with a slight predominance in men. It rarely occurs before middle age and its prevalence increases steadily with age [2]. The exact etiology of PD is unknown, but genetic and environmental factors may play a role in its pathogenesis. Viral infection has been suggested to play a pathogenic role.

PD results in weakened bone strength and abnormal bone architecture and is often asymptomatic, but patients can present with pain, deformity or, depending on the bone involved, fracture in the affected bone [3]. This structural weakness may be unfavorable for the placement of osseointegrated dental implants.

Currently, bisphosphonates are administered for the treatment of PD because they effectively restore bone mineral density, bone strength, and reduce the incidence of bone fracture [3]. However, bisphosphonate exposure has been linked to osteonecrosis of the jaw.

Systemic factors may affect bone healing around dental implants [4]. However, despite a reduced success rate, unfavorable systemic conditions are not always absolute contraindications for bone augmentation and dental implant placement [5].

In this report, we describe a successful case of dental implant placement in an 86-year-old woman diagnosed with Paget's disease and treated with oral bisphosphonates.

Case Description

An 86-year-old woman was referred for implant treatment. Her medical history was significant because, she was diagnosed with Paget's disease (alkaline phosphatase 1500 U/l) in 1988. A lateral x-ray of the cranium showed the typical radiopaque image, particularly in the frontal and parietal bones (Figure 1).

At the time of diagnosis, blood tests showed increased levels of alkaline phosphatase (1500 U/l; normal: 27-100 U/l) and normal calcium (10.2 mg/dl; normal: 9-10.4 mg/dl) and phosphorus (4.0 mg/dl; normal: 2.3-4.1 mg/dl) levels.

The main symptom presented by the patient was the hearing loss caused by the disease. The patient received treatment with sodium alendronate (Fosamax) at 70 mg once a week and remains on this drug.

Intraoral examination revealed that the patient was completely edentate. The patient was wearing only a lower dental prosthesis and complained of instability. Panoramic radiograph and computerized tomographic images revealed several low bone density areas and favorable bone dimensions.

The treatment plan included the installation of an upper dental prosthesis and the placement of 4 dental implants (Neodent) three 11 mm in length, 3.75 in diameter implants

and one 10 mm in length, 4.3 in diameter implant. After fixation in the anterior portion of the mandible, the implants showed satisfactory clinical primary stability. The distribution of implants in the mandible is shown in Figure 2.

Six months after the surgery, a fixed full arch denture was anchored to the implants (Figure 3). The patient was followed for a period of 6 years, after which no clinical mobility or signs of loosening were observed, and the implants were successfully osseointegrated (Figure 4).

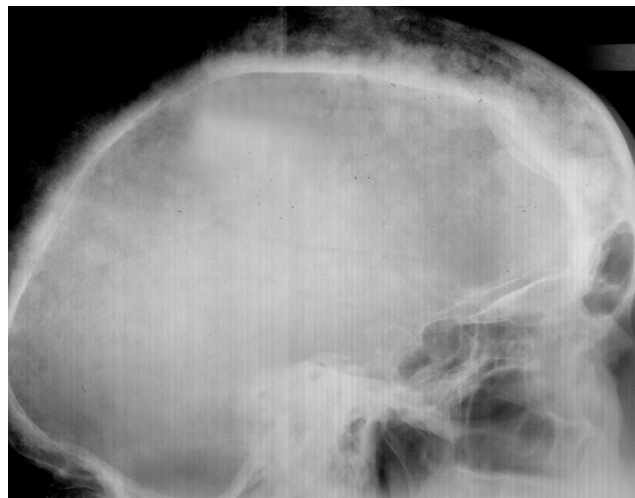

Fig. 1. A lateral skull radiograph showing a radiopaque image with a cotton wool appearance typical of PD, mainly in the frontal and parietal bones.

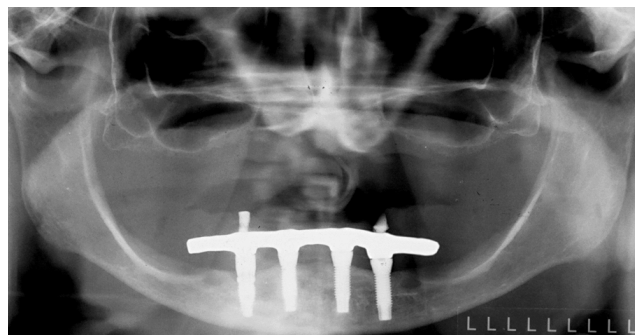


Fig. 2. A panoramic radiograph showing edentulism. The radiopaque images reveal the presence of four dental implants in the anterior-inferior region.

Discussion

Primary implant stability plays a major role in successful osseointegration, and it depends largely on local bone quality and quantity as well as the use of an appropriate dental implant and surgical technique.

Studies have reported some systemic disorders as contraindications for dental endosseous implant treatments;

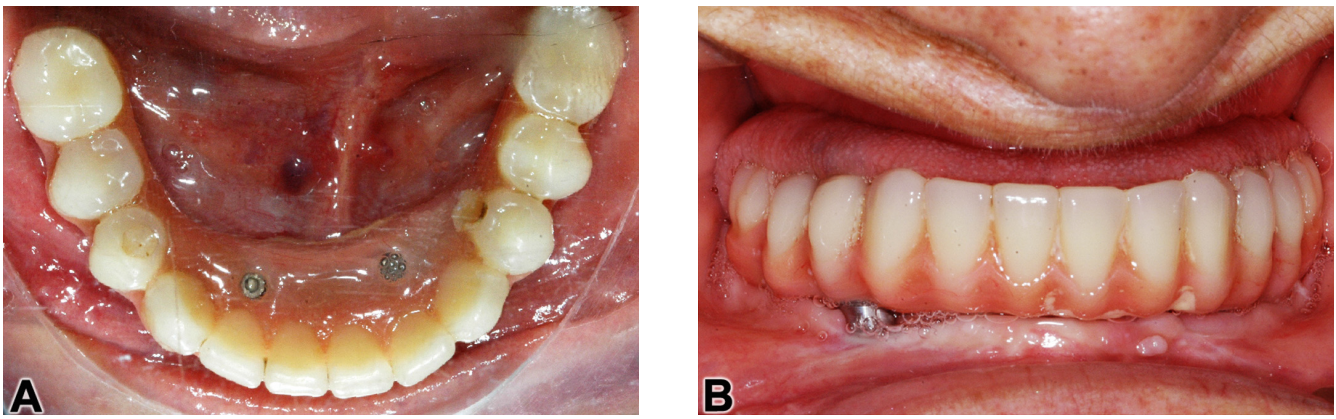


Fig. 3. An occlusal view of the implant prosthodontics (A). A frontal view of the prosthesis on the implant (B).

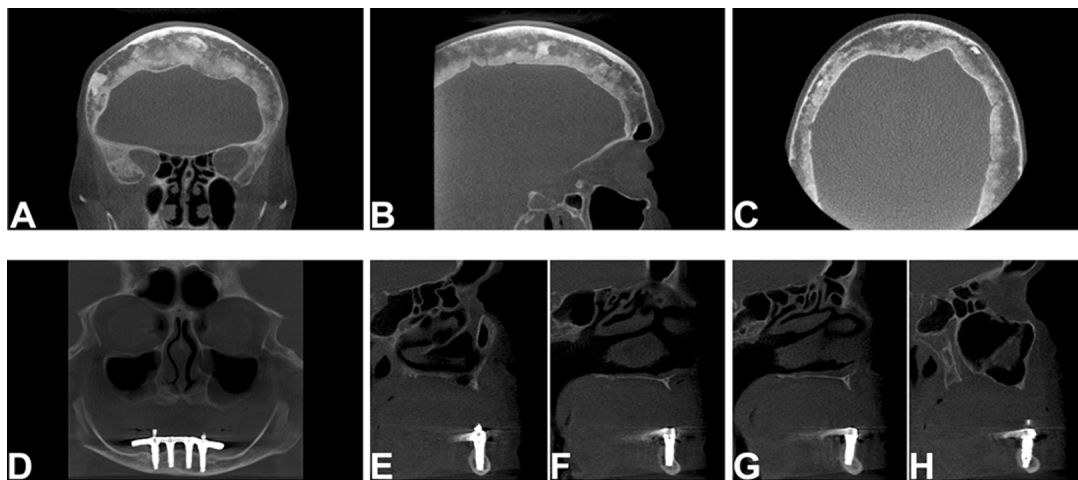


Fig. 4. Cone beam tomography showing hyperdense images in the frontal and parietal bones, featuring a predominance of sclerotic areas (A, B and C). The panoramic image (D) and para-axial slices (E, F, G and H) show hyperdense areas related to the implants. Radiographic controls after four years.

these include recent myocardial infarction, cerebral-vascular accidents, valvular prosthesis surgery, immunosuppression, bleeding issues, active treatment of malignancy, drug abuse, psychiatric illness, and intravenous bisphosphonate uptake [6].

Other contraindications include adolescence, older age, smoking, diabetes, positive interleukin-1 genotype, cardiovascular problems and diseases that affect bone quality, such as osteoporosis and PD [4,7].

Paget's disease is a disorder in which there is a marked increase in bone turnover in localized parts of the skeleton. This results in abnormal bone structure, leading to expansion, structural weakness resulting in deformity and an increased risk of fracture, and pain.

Bisphosphonate is the most frequently used pharmacological treatment for PD. This antiresorptive drug inhibits the function, activation, and survival of osteoclasts [8]. The use of these drugs in the treatment of PD is controversial because there have been reports of osteonecrosis of the

jaw associated with the administration of intravenous bisphosphonates. Therefore, it is necessary to carry out further research to evaluate the results, comparability, appropriate dosages and side effects for each clinical application of these drugs [9].

The signs and symptoms observed before the clinical detection of ONJ may include pain, mucosal swelling, erythema, ulceration and loose teeth. It has been observed that these lesions occur more frequently in the mandible than in the maxilla (2:1 ratio) [10]. A retrospective study involving 1580 patients showed that 65% of cases occurred in the mandible and 27% in the maxilla [11].

Recent studies have demonstrated that the risk of developing osteonecrosis as a result of antiresorptive therapy is low. Additionally, there seems to be no significant difference in implant success rates following bisphosphonate treatments. Therefore, antiresorptive therapy seems to be a contra-indication for the placement of dental implants. However, studies are needed to determine whether implants



placed in patients exposed to antiresorptive agents perform as well as those placed in patients who have not been exposed to these agents [12].

In 2007, the American Association of Oral and Maxillofacial Surgeons offered performance guidelines for patients treated with bisphosphonates. If administered intravenously, the placement of dental implants is contraindicated. If they are taken orally, three possibilities exist: a) if the patient has been treated for less than 3 years and has no clinical risks, dental implants can be placed without altering the conventional surgical treatment; b) if the patient has been treated for less than 3 years and is treated jointly with corticoids, bisphosphonates must be discontinued 3 months before implant surgery and not administered again until the bone has completely healed; and c) if the patient has been treated for more than 3 years it is possible to place dental implants if the bisphosphonates are discontinued 3 months before surgery and not administered again until the bone has completely healed [13].

To date, few cases have described the placement of dental implants in patients with PD. However, it is possible to find examples in which the treatment was successful even under unfavorable bone density conditions, such as those considered "poor" [14] or with standard "cotton balls" findings, such as the present case.

Removable prostheses typically become uncomfortable, as illustrated in this case. The patient complained of instability of the prosthesis because PD can cause deformities and pathological fractures to the facial bones. Therefore, treatment with dental implants results in an increased quality of life, because it provides comfort and safety for the patient [15].

Therefore, even in cases in which the bone is considered "poor", it is possible to obtain satisfactory results, if the protocol is followed properly and, the best treatment for the case is chosen. Furthermore, the patient should be informed of the risks of all procedures to, increase awareness of the possible failures that may occur, including osteonecrosis of the jaw associated with bisphosphonates and the possibility of implant loss over the long term.

Conclusion

We presented a case in which a patient with PD treated with bisphosphonates received 4 dental implants. Based

on the good stability of the implants, the absence of signs of inflammation and the absence of images indicative of resorption, we conclude that the administration of bisphosphonates to patients with PD does not prohibit the successful installation and proper osseointegration of dental implants. However, additional research is needed to confirm these findings.

References

1. Whyte MP. Clinical Practice. Paget's disease of bone. *N Engl J Med* 2006; 355:593-600.
2. Michou L, Brown JP. Emerging strategies and therapies for treatment of Paget's disease of bone. *Drug Des Devel Ther* 2011;5:225-39.
3. Bi Y, Gao Y, Ehrchiou D, Cao C, Kikuri T, Le A, et al. Bisphosphonates cause osteonecrosis of the jaw-like disease in mice. *Am J Pathol* 2010; 177(1):280-90.
4. Alsaadi G, Quirynen M, Michiles K, Teughels W, Komárek A, van Steenberghe D. Impact of local and systemic factors on the incidence of failures up to abutment connection with modified surface oral implants. *J Clin Periodontol* 2008; 35(1):51-7.
5. Erdogan O, Shafer DM, Taxel P, Freilich MA. A review of the association between osteoporosis and alveolar ridge augmentation. *Oral Surg Oral Med Oral Pathol Oral Radiol Endod* 2007; 104(6):738 e1-13.
6. Hwang D, Wang HL. Medical contraindications to implant therapy: part I: absolute contraindications. *Implant Dent* 2006; 15:353-60.
7. Hwang D, Wang HL. Medical contraindications to implant therapy: part II: relative contraindications. *Implant Dent* 2007; 16:13-23.
8. Chung PY, Van Hul W. Paget's disease of bone: evidence for complex pathogenetic interactions. *Semin Arthritis Rheum* 2011; 41(5):619-41.
9. Otomo-Corgel J. Implants and oral bisphosphonates: risky business? *J Periodontol* 2007; 78(3):373-6.
10. Sarasquete M, González M, San Miguel JF, García-Sanz R. Bisphosphonate-related osteonecrosis: genetic and acquired risk factors. *Oral Diseases* 2009; 15(6):382-7.
11. Filleul O, Crompot E, Saussez S. Bisphosphonate-induced osteonecrosis of the jaw: a review of 2,400 patient cases. *J Cancer Res Clin Oncol* 2010; 136(8):1117-24.
12. Hellstein JW, Adler RA, Edwards B, Jacobsen PL, Kalmar JR, Koka S, et al. Managing the care of patients receiving antiresorptive therapy for prevention and treatment of osteoporosis: Executive summary of recommendations from the American Dental Association Council on Scientific Affairs. *JADA* 2011; 142:1243-51.
13. Flichy-Fernández A-J, Balaguer-Martínez J, Peñarocha-Diago M, Bagán JV. Bisphosphonates and dental implants: Current problems. *Med Oral Patol Oral Cir Bucal* 2009; 14(7):E355-60.
14. Rasmussen JM, Hopfensperger ML. Placement and restoration of dental implants in a patient with Paget's Disease in remission: literature review and clinical report. *Journal of Prosthodontics* 2007; 17:35-40.
15. Torres J, Tamimi F, Garcia I, Herrero A, Rivera B, Sobrino JA, et al. Dental implants in a patient with Paget disease under bisphosphonate treatment: A case report. *Oral Surg Oral Med Oral Pathol Oral Radiol Endod* 2009; 107(3):387-92.

